

Hepatitis A and hepatitis E virus co-infection with right pleural effusion, ascites and acute acalculous cholecystitis. A case report

Coinfección por el virus de la hepatitis A y la hepatitis E con derrame pleural derecho, ascitis y colecistitis acalculosa aguda. Reporte de caso

Luis Piza Palacios^{1,a}, Jorge Espinoza- Ríos^{1,b,2,3}

¹ School of Medicine, Universidad Peruana Cayetano Heredia, Lima, Peru.

² Gastroenterology Department, Hospital Cayetano Heredia, Lima, Peru.

³ Gastroenterology Department, Clínica San Felipe, Lima, Peru.

^a Student, ^b faculty member

Recibido: 12/11/19

Aprobado: 27/01/20

ABSTRACT

Hepatitis A and hepatitis E are the leading causes of acute viral hepatitis in developing countries due to our poor sanitary conditions, both spread by fecal-oral route or through contaminated water and food. Being both self-limiting diseases, they are usually benign but may present with atypical clinical findings. A 32 year-old female with right pleural effusion, ascites and acalculous cholecystitis during the course of HAV and HEV co-infection is reported. Clinical improvement was observed with conservative management. As far as we know, this is the first case described of a patient with these three complications in the background of a hepatitis A virus and hepatitis E virus co-infection.

Keywords: Hepatitis A; Hepatitis E; Acalculous cholecystitis; Pleural effusion; Ascites (source: MeSH NLM).

RESUMEN

Hepatitis A y hepatitis E son las principales causas de hepatitis viral en países en desarrollo debido a las limitadas condiciones sanitarias. Son condiciones usualmente benignas y autolimitadas, pero pueden presentarse de forma atípica. Se reporta una paciente de 32 años con efusión pleural derecha, colecistitis acalculosa y ascitis en el curso de una co-infección por el virus de Hepatitis A y hepatitis E. Hasta donde tenemos conocimiento, este es el primer caso de una paciente con estas tres complicaciones como resultado de una infección por el virus de hepatitis A y hepatitis E.

Palabras clave: Hepatitis A; Hepatitis E; Colecistitis acalculosa; Efusión pleural; Ascitis (fuente: DeCS BIREME).

INTRODUCTION

Both hepatitis A virus (HAV) and hepatitis E virus (HEV) are leading causes of acute viral hepatitis in developing countries due to poor sanitary conditions. These viruses spread by the fecal-oral route or through contaminated water and food. The prevalence of HAV and HEV co-infection has been reported⁽¹⁻³⁾, however, there are only few studies about its clinical presentation^(4,5).

Although these are self-limited infections and present with mild symptoms, extrahepatic manifestations are reported in both of them, mostly in pediatric patients. These include pleural effusion, gallbladder abnormalities ascites, glomerulonephritis, cryoglobulinemia, thrombocytopenia, agranulocytosis, aplastic anemia, pancreatitis, among others⁽⁵⁻⁹⁾. We report the first case – to the best of our knowledge –

of a patient with three of these complications, in the context of a HAV and HEV dual infection.

CASE REPORT

A 32-year-old woman was admitted to the clinic with two days history of intense epigastric pain, nausea, vomiting and dark urine. There was no significant medical history. She had traveled to Colombia two weeks before admission. She was afebrile with normal vital signs. On physical examination, she was icteric, had epigastric tenderness, positive Murphy sign and liver was not palpable.

Laboratory examination yielded the following: hemoglobin: 14.4 g/dL, hematocrit: 41.8%, white blood cell count: 3,100 cells/mm³, platelet count: 200,000 cells/mm³, amylase: 73 U/L, total bilirubin:

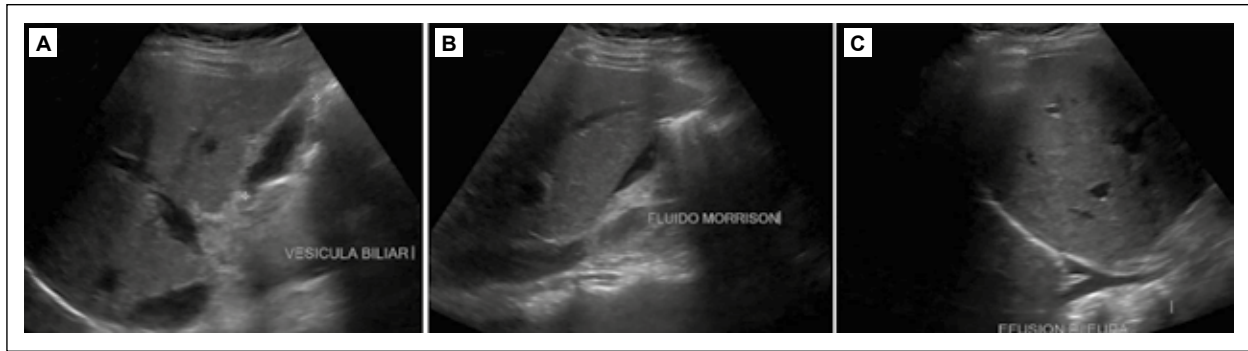


Figure 1: A) Thickening of gallbladder wall (9 mm) on the day of admission. B) Free liquid in the hepatorenal recess and right paracolic recess. C) Right pleural effusion on the 4th day of admission.

2.62 mg/dL, direct bilirubin: 2.55 mg/dL, aspartate aminotransferase: 2,066 U/L, alanine aminotransferase: 2,915 U/L, gamma-glutamyl transferase: 85.4 U/L, alkaline phosphatase: 71 U/L and c-reactive protein: 6.2 mg/L, HAV IgM was positive; INR, electrolytes, albumin and glucose were in the normal ranges. An abdominal ultrasound showed a thickened (9 mm) not calculous gallbladder (Figure 1A). The diagnosis of hepatitis A with acute reactive cholecystitis was established.

On the 4th day of admission, the patient persisted with abdominal pain and presented abdominal distention. A second ultrasound revealed ascites with perihepatic and perisplenic fluid (Figure 1B) and right pleural effusion (Figure 1C). IgM for Hepatitis E virus was positive. Serological markers for Hepatitis B virus and Hepatitis C virus were interpreted as negative. She was managed with supportive parenteral fluids and eventually a low-fat diet, and clinical improvement was seen over the next days. Hepatic enzyme levels raised initially, but gradually returned to normal values within a four-month follow-up (Table 1), in which the patient continued to do well, showing no sonographic signs of extrahepatic manifestations.

DISCUSSION

Hepatitis A is generally an acute, self-limiting liver infection transmitted through the fecal-oral route by a positive-strand RNA virus, the hepatitis A virus (HAV),

which causes 10 million infections worldwide each year⁽¹⁰⁾. Serological and molecular studies have shown that hepatitis E virus (HEV) is globally distributed and is the leading cause of enterically transmitted viral hepatitis illness worldwide. It is estimated that two billion people worldwide are infected with HEV every year, with 14 million symptomatic cases and 300,000 deaths⁽¹¹⁾. Considering the similar epidemiological profile of both viruses, it is unsurprising that a dual infection is not uncommon. A cross-sectional study conducted in India reported that the prevalence of both HAV and HEV in patients with acute viral hepatitis was 11.5%⁽¹⁾. Another study in Cuba demonstrated that such coinfection is up to 12.8% of cases of acute viral hepatitis⁽³⁾; unfortunately, there is a lack of data regarding the clinical manifestations and natural history of this under-reported condition.

Although both infections usually present with clinical manifestations that are mainly limited to liver inflammation; both viruses, especially HAV, may present with complications, such as cholecystitis, pleural effusion and ascites. The prevalence of these complications is not as unusual as previously thought. In a recent retrospective study, findings were collected from ultrasound examinations and laboratory data from 43 adult patients with HAV infection who were admitted to the "Hadassah-Hebrew University Medical Center" between 2004-2016. Ascites was noted in 8 patients, a thickened gallbladder wall was observed in 14, pericholecystic fluid in 8 and biliary sludge in 4⁽⁶⁾.

Table 1. Follow-up of hepatic enzyme levels.

Test	Day 1	Day 2	Day 4	Day 7	Day 16	Day 38	Day 115
Aspartate aminotransferase (U/L)	2,066	3,124	3,477	678	73	52	25
Alanine aminotransferase (U/L)	2,915	3,634	4,146	2,030	269	80	35
Alkaline phosphatase (U/L)	71	77	82	95	85	46	24
Gamma-glutamyl transferase (U/L)	85.4	84.6	80.1	100.2	77.1	37.6	9.5
Direct bilirubin (mg/dL)	2.55	4.19	5.82	7.37	2.06	0.50	0.15
Total bilirubin (mg/dL)	2.62	4.44	6.39	8.33	2.44	0.95	0.34

Ascites in liver diseases may occur as a result of venous and lymphatic obstruction or hypoalbuminemia; as albumin levels were in the normal range in our patient, an increase in venous or lymphatic pressure due to the compression of hepatic sinusoids may explain the occurrence of ascites in this case ⁽¹²⁾.

Pleural effusion may be secondary to ascites due to fluid transport through the diaphragmatic lymphatics or direct passage through a diaphragmatic defect ⁽¹²⁾, or due to deposit of immune complexes ^(7,8). Gallbladder abnormalities are also reported, being gallbladder thickening the most common. One possible mechanism is that it occurs when hepatocyte injury at the onset of HAV infection causes a temporary decrease in bile production and excretion. A second hypothesis is that HAV contained in bile juice causes a direct injury to the gallbladder mucosal and muscular layers. Another hypothesis is that hepatocyte necrosis causes inflammatory reaction in the tissues surrounding the liver, including the gallbladder wall ⁽¹³⁾, and possibly the pleura.

Despite of not being uncommon, since three of the complications were seen in the same patient at the same time, we suggest that the HAV and HEV co-infection must have played a synergic role causing inflammation in tissues surrounding the liver, possibly due to deposit of immune complexes that finally led to this unusual presentation.

In conclusion, our case represents a unique manifestation of a dual infection with Hepatitis A and Hepatitis E. The goal with this report is to emphasize the possibility of a coinfection of this kind, in the context of an immunocompetent patient who presents the clinical findings mentioned above.

Conflict of interest: The authors have no potential conflicts of interest.

REFERENCES

1. Rao P, Shenoy MS, Baliga S, Joon A. Prevalence of HAV and HEV in the patients presenting with acute viral hepatitis. *BMC Infect Dis.* 2012;12(Suppl 1):P30.
2. Realpe-Quintero M, Mirazo S, Viera-Segura O, Copado-Villagrana ED, Panduro A, Roman S, *et al.* Hepatitis e Virus Genotype 1 and Hepatitis A Virus Dual Infection in Pediatric Patients with a Low Socioeconomic Status from Mexico. *Intervirol.* 2018;61(3):105-10.
3. Lay LDLAR, Quintana A, Villalba MCM, Lemos G, Corredor MB, Moreno AG, *et al.* Dual infection with hepatitis A and E viruses in outbreaks and in sporadic clinical cases: Cuba 1998-2003. *J Med Virol.* 2008;80(5):798-802.
4. Naha K, Karanth S, Prabhu M, Sidhu MS. Dual infection with hepatitis A and E virus presenting with aseptic meningitis: A case report. *Asian Pac J Trop Med.* 2012;5(7):587-8.
5. Kumar KJ, Kumar HCK, Manjunath VG, Umesh L. Pleural effusion: A rare complication of co-infection of hepatitis A and hepatitis E. *Ann Trop Med Public Heal.* 2012;5(5):532-3.
6. Israel S, Fruchtman H, Hakimian D, Ackerman Z. Ascites and gallbladder abnormalities are frequent findings in adults with hepatitis a virus infection. *Isr Med Assoc J.* 2019;21(1):24-8.
7. Amarapurkar DN, Amarapurkar AD. Extrahepatic manifestations of viral hepatitis. *Ann Hepatol Off J Mex Assoc Hepatol.* 2002;1(4):192-5.
8. Prasad AN. Hepatitis A: An unusual presentation. *Med J Armed Forces India.* 2006;62(4):389.
9. Yılmaz-Çiftdoğan D, Köse E, Aslan S, Gayyurhan E. Atypical clinical manifestations of hepatitis a among children aged 1-16 years in South-Eastern region of Turkey. *Turk J Pediatr.* 2015;57(4):339-44.
10. Jacobsen KH, Wiersma ST. Hepatitis A virus seroprevalence by age and world region, 1990 and 2005. *Vaccine.* 2010;28(41):6653-7.
11. Kimura H, Ito Y, Suzuki R, Nishiyama Y. Measuring EBV Viral Load: the significance and application for each EBV-associated disease. *Rev Med Virol.* 2008;18:305-19.
12. Gürkan F. Ascites and pleural effusion accompanying hepatitis A infection in a child. *Clin Microbiol Infect.* 2000;6(5):286-7.
13. Kim MY, Baik SK, Choi YJ, Park DH, Kim HS, Lee DK, *et al.* Endoscopic sonographic evaluation of the thickened gallbladder wall in patients with acute hepatitis. *J Clin Ultrasound.* 2003;31(5):245-9.

Correspondencia:

Luis Antonio Piza Palacios

Manuel Tovar 541 Int. 101, Miraflores, Lima, Perú.

E-mail: luis.piza.p@upch.pe