

Intraductal papillary neoplasia of the bile duct (IPNB): case report and literature review

Neoplasia papilar intraductal de la vía biliar (IPNB): reporte de caso y revisión de la literatura

Rómulo Vargas^{1,2}, Oscar Patarroyo^{1,2}, Raúl Cañadas^{1,2}, Alan Ovalle^{1,2}

¹ Pontificia Universidad Javeriana, Bogotá, Colombia.

² Gastroenterology Unit, Hospital Universitario San Ignacio, Bogotá, Colombia.

Recibido: 28/06/2020 - Aprobado: 30/09/2020

ORCID: Rómulo Darío Vargas Rubio: <http://orcid.org/0000-0001-5660-6229>, Oscar Javier Patarroyo Henao: <https://orcid.org/0000-0001-6050-7450>, Alan Felipe Ovalle Hernández: <https://orcid.org/0000-0001-8626-1567>, Raúl Antonio Cañadas Garrido: <http://orcid.org/0000-0003-2938-7731>

ABSTRACT

Intraductal papillary neoplasm of the bile duct (IPNB) is a rare premalignant condition, defined as an epithelial neoplasm of the bile duct with exophytic papillary growth that can develop in any segment of the biliary tree. This pathology, with the highest prevalence in Asia, has been associated with the presence of hepatolithiasis and eastern liver infection (clonorchiasis). The diagnosis will depend on the clinical suspicion against the findings evidenced in the different diagnostic supports (invasive and non-invasive). Curative resection with negative margins is the treatment of choice in patients candidates for surgical management. In the event that the patient is not a candidate for curative resection, palliative treatment includes chemotherapy, percutaneous and endoscopic drainage, laser cholangioscopy ablation and intraluminal therapy with iridium 192. We present two cases of two patients with a diagnosis of IPNB confirmed by histology treated at our institution. The first case in an 86-year-old patient had a history of recurrent obstructive biliary syndrome and clinical suspicion of a new episode of cholangitis, and the second case in a 73-year-old patient who had a disseminated infectious process (spondylodiscitis, pelvic and intra-abdominal abscesses), and with the clinical suspicion of presenting a primary hepatobiliary focus. Both patients underwent single-operator cholangioscopy plus biopsy, confirming the diagnosis by histology. The first case was managed with palliative intent, indicating endoscopic diversion of the bile duct, while surgical management was indicated in the second case.

Keywords: *Bile duct neoplasms; Cholangiocarcinoma; Cholangitis (source: MeSH NLM)*

RESUMEN

La neoplasia papilar intraductal de la vía biliar (NPIB) es una enfermedad premaligna poco frecuente, definida como una neoplasia epitelial de la vía biliar con crecimiento papilar exofítico que puede desarrollarse en cualquier segmento de la vía biliar. Esta patología, de mayor prevalencia en Asia, se ha asociado a la presencia de hepatolitiasis e infección hepática oriental (clonorchiasis). El diagnóstico dependerá de la sospecha clínica frente a los hallazgos evidenciados en los diferentes soportes diagnósticos (invasivos y no invasivos). La resección curativa con márgenes negativos es el tratamiento de elección en pacientes candidatos a manejo quirúrgico. En el caso de que el paciente no sea candidato a resección curativa, el tratamiento paliativo incluye quimioterapia, drenaje percutáneo y endoscópico, ablación por colangioscopia láser y terapia intraluminal con iridio 192. Presentamos dos casos de dos pacientes con diagnóstico de NPIB confirmado por histología tratado en nuestra institución. El primer caso de un paciente de 86 años con antecedentes de síndrome biliar obstructivo recurrente y cursando con un nuevo episodio y sospecha de colangitis aguda, y el segundo caso en un paciente de 73 años que presentaba un proceso infeccioso diseminado (espondilodiscitis, abscesos pélvicos e intraabdominales), con sospecha clínica de presentar un foco hepatobiliar primario. Ambos pacientes fueron sometidos a colangioscopia más biopsia, confirmando el diagnóstico por histología. El primer caso se manejó con intención paliativa, indicando derivación endoscópica de la vía biliar, mientras que en el segundo se indicó manejo quirúrgico.

Palabras clave: *Neoplasias de los conductos biliares; Colangiocarcinoma; Colangitis (fuente: DeCS BIREME).*

INTRODUCTION

Intraductal papillary neoplasms of the bile duct (IPNB) is a rare variant of bile duct tumors, and based on the latest World Health Organization (WHO) classification in 2010, is characterized by a papillary neoplasm or villous biliary covering delicate fibrovascular stalks and histological spectrum ranging from benign disease to invasive malignancy⁽¹⁾.

Attention has been drawn to biliary tumors with macroscopically visible mucin secretion, which show predominantly papillary growth within the dilated bile duct lumen and secrete a large amount of mucin⁽²⁻³⁾. IPNB presents as an intraductal mass within the dilated intrahepatic or extrahepatic bile ducts on imaging studies. Many terms have also been used to describe this disease including biliary papillomatosis, mucin-hypersecreting intrahepatic biliary neoplasm,

mucinosus cholangiocarcinoma, biliary intraductal papillary neoplasm of the liver, ductectatic mucinous cystadenocarcinoma, and biliary intraductal papillary neoplasm⁽²⁾. The new concept IPNB is the biliary counterpart of intraductal papillary mucinous neoplasm (IPMN) of the pancreas, has been suggested. IPNB with low- or intermediate- and high-grade intraepithelial neoplasia are regarded as premalignant and non-invasive IPNB, whereas IPNB with an associated invasive carcinoma is considered malignant and invasive IPNB⁽¹⁻³⁾. In this case report and literature review, we describe two cases, IPNB concept, clinical, pathologic, and suggested treatment.

CASES REPORT

Case 1

Comorbid 86-year-old female patient, with a history of cholecystectomy by laparoscopy for symptomatic cholelithiasis in 2018, who presented recurrent obstructive biliary syndrome of two years of evolution, requiring endoscopic intervention of the bile duct by endoscopic retrograde cholangiopancreatography (ERCP) on 5 occasions, and surgical exploration of the bile duct, with cholangiography repeatedly showing an image suggestive of recurrent choledocholithiasis. She was admitted to our institution for emergencies, referred from the outpatient clinic on suspicion of acute cholangitis. On admission, the patient is hemodynamically stable, without respiratory distress in the absence of signs of a systemic inflammatory response, without abdominal pain, asymptomatic. Admission laboratories show as the only positive

finding a hemogram with leukocytosis (14,800/ul). Kidney, liver function, amylase, electrolyte levels, acute phase reactants, serum lactate, urinalysis, and chest radiography are within normal limits. A total abdomen ultrasound was performed, identifying a dilated extrahepatic bile duct (12 mm) as positive findings in the presence of pneumobilia, with a normal intrahepatic bile duct.

She was evaluated by gastroenterology, considering the suspicion of acute cholangitis (Tokyo 2018 A2 + C2 criteria), indicating empirical antimicrobial coverage with Ampicillin and Sulbactam. She carried to ERCP, a large duodenal papilla with a large infundibulotomy opening was observed on duodenoscopy. Deep cannulation of the bile duct is performed on the first attempt with an extractor balloon, observing in cholangiography by occlusion a normal intrahepatic bile duct with a dilated extrahepatic bile duct (12 mm common bile duct), identifying the presence of multiple fixed filling defects, which displace the balloon during its removal (Figure 1 A, B and C), obtaining the exit of mucoid material through the papilla. Given the suspicion of a coledocian tumor lesion due to the findings, a single operator (Spyglass, Boston Scientific) choledochoscopy was performed at the same endoscopic time, identifying multiple exophytic lesions of papillomatous appearance, lobed patterned at the distal and middle level and vascular irregularity (Figure 1 D and E), from which biopsies were taken with Spy-bite (Figure 1F).

Exploration of proximal common bile duct and hepatic common duct without evidence of lesions, with a usual mucosal and vascular pattern, inserting a plastic

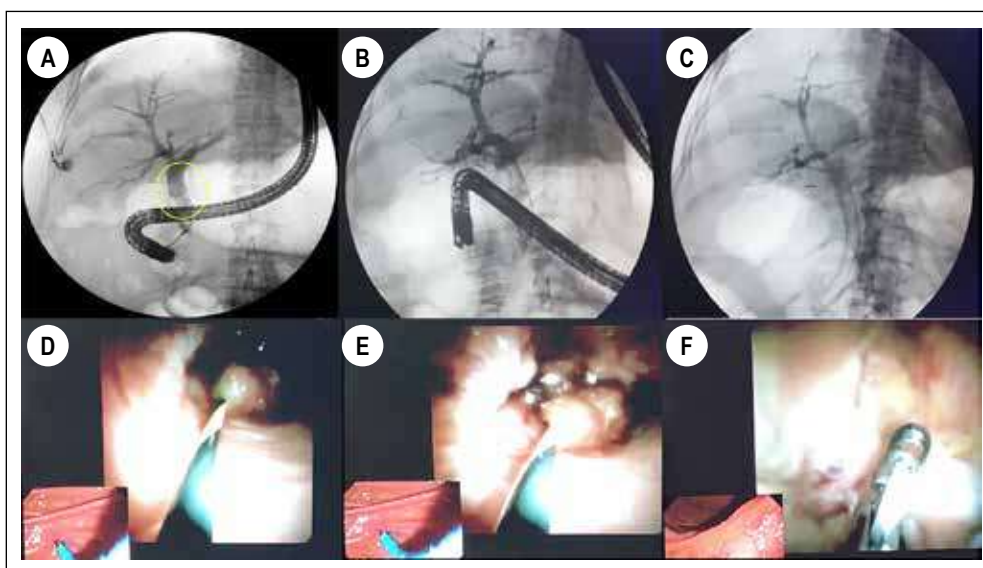
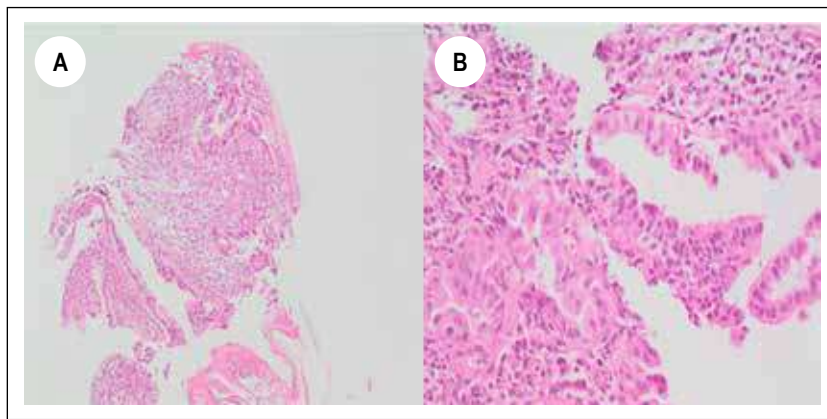


Figure 1. A, B and C. ERCP observing a 12 mm common bile duct in the cholangiography, identifying the presence of multiple fixed filling defects in the middle and distal bile duct. D and E. Cholangioscopy (Spyglass) identifying several exophytic lesions with papillomatous appearance in common bile duct. F. Biopsy of papillomatous lesions described with Spy-scope.



Figures 2. Hematoxylin-Eosin stain showing fragments of biliary epithelium with chronic inflammation, as well as fragments of a tubular-papillary configuration neoplastic lesion with high-grade dysplastic changes.

biliary stent of 10 Fr x 7 cm, without complications. The pathology report is conclusive for an intraductal papillary neoplasm of the bile duct with high-grade dysplastic changes (Figure 2 A and B). After her discharge from the hospital, she was evaluated by the biliopancreatic diseases service of our institution, considering herself together with family members and taking into account the clinical status and functionality of the patient not a candidate for surgical management, indicating the insertion of a metallic biliary stent uncovered (10 mm x 80 mm), procedure performed without complications.

Case 2

A 73-year-old female patient who required prolonged extra-institutional hospitalization before a bacterial liver abscess and secondary abdominal sepsis, with *K. pneumoniae* isolation in blood cultures was admitted to our institution with a 2-month history of fever associated with low back pain, with progressive loss of strength in lower limbs. Nuclear magnetic resonance with gadolinium, of the lumbosacral spine confirms the presence of spondylodiscitis at the T11-T12 and T12-L1 level with pathological T12 fracture, as well as extensive multiloculated collections in the psoas muscles, suggestive of abscesses at this level. Complementary contrast CT scan of the abdomen confirms the presence of collections at the level of the psoas muscles (right 102x26x27 mm and left 100x18x22 mm) as well as liver collections (larger than 42x13 mm) and suggestive changes and infectious spondylitis, indicating empirical antimicrobial coverage with meropenem. Drainage of the hepatic, psoas and vertebral collections was performed by interventional radiology, obtaining fluid with purulent characteristics, with isolation of cultures of a *K. pneumoniae* of the usual pattern, indicating completion of 42 days of directed antibiotic management. Given the presence of a disseminated

infectious process with an unclear focus and the suspicion of being of hepatobiliary origin, we decided to perform a complementary cholangioresonance, which identified a filling defect at the level of the proximal bile duct as a positive finding. Taking these findings into account, we consider performing ERCP (Figure 3) plus single-operator cholangioscopy (Spyglass), observing immediately below the confluence of the hepatic ducts a raised, hairy-looking lesion of prominent vessels of approximately 20 mm long, non-obstructive, suggesting the diagnosis of cholangiocarcinoma due to its characteristics. Biopsy is performed with the Spy-bite device, with an inconclusive pathology report, considering a new ERCP plus biopsy taking with conventional forceps guided by fluoroscopy. The pathology report of this new sample is compatible with an intraductal papillary neoplasm of the bile duct (Figure 4).

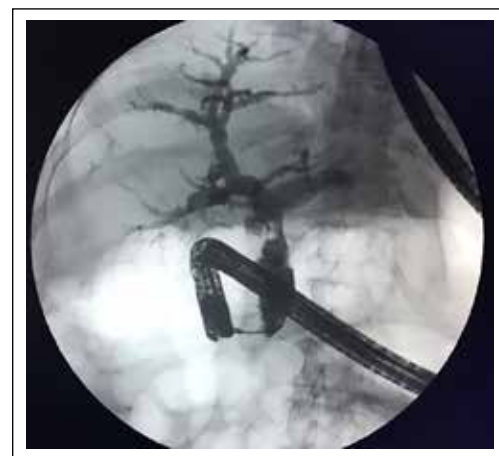

Figure 3. ERCP observing a dilated common bile duct in the cholangiography, identifying the presence of a filling defect in the proximal segment.

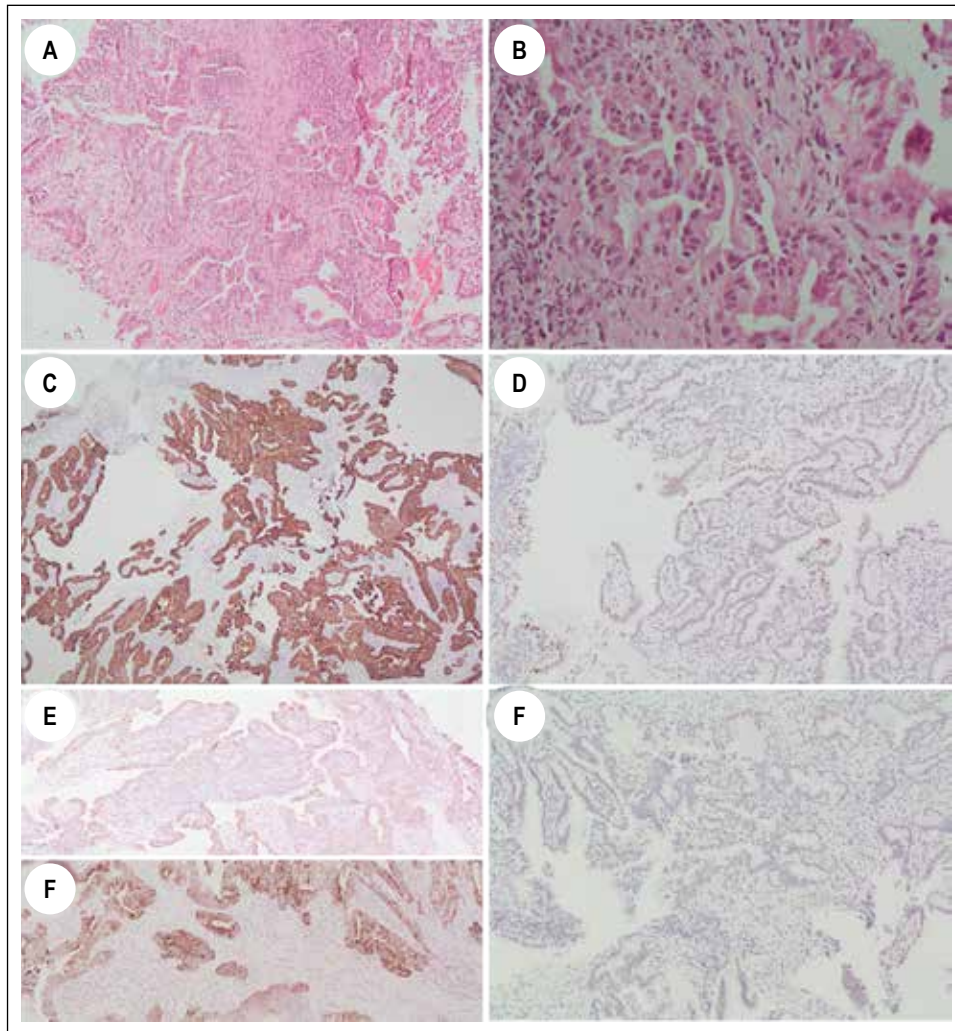


Figure 4. A and B. Hematoxylin-Eosin staining showing fragments of a tubulopapillary neoplasm lined by cubic epithelial cells with moderately pseudostratified pleomorphic nuclei. C and D. Immunohistochemistry study showing positivity of neoplastic cells for CK7 and CDX2. E and F. Immunohistochemistry study showing expression of neoplastic cells for MUC-1 and MUC2. G. Immunohistochemical study shows negativity of the tumor lesion for CK20.

DISCUSSION

Intraductal papillary neoplasm of the bile duct (IPNB) is a rare neoplasm, defined as an epithelial tumor of the bile duct characterized by a papillary growth pattern of an exophytic nature, which generates the formation of intraductal papillary masses that can develop in any segment of the biliary tree ⁽¹⁻³⁾.

First described in 1976 with the name of multicenter biliary papillomatosis associated with invasive adenocarcinoma ⁽⁴⁾, it is until 2001 that Chen and Nakamura first proposed the term IPNB in the presence of a single tumor made up of multifocal papillary epithelial lesions with or without mucin production in the presence of bile duct dilation ^(5,6). In 2006 Zen and collaborators proposed the term IPNB to group biliary papillary tumors (biliary papillomatosis and papillary cholangiocarcinoma) as a single entity, the biliary

counterpart to intraductal papillary mucinous neoplasia (IPMN-P) ⁽⁷⁾. In 2010, the World Health Organization (WHO) in its fourth edition, includes these types of tumors as precursor lesions for cholangiocarcinoma, establishing two categories of mucin-producing tumors of the bile duct: cystic mucinous neoplasia and intraductal papillary neoplasia ^(1,4,8), classifying IPNBs into 4 groups: IPN with low-grade, intermediate, high-grade intraepithelial dysplasia, and IPN associated with invasive carcinoma. Histologically it is characterized by a papillary or tubulopapillary architecture, with four histological subtypes being defined: pancreatobiliary (most common), intestinal, gastric, and oncocytic ⁽³⁾.

Because IPNB is a recently categorized and defined pathology, there are few works that cover this condition, and therefore, little is known about its morphological and clinicopathological characteristics. It is a tumor with wide geographic variation, mainly

identified in eastern countries such as Taiwan, Japan, North and South Korea, where hepatolithiasis and clonorchiasis (parasitic zoonosis caused by the liver fluke or *Clonorchis sinensis*) are endemic. In western countries, its presentation is sporadic and of unknown etiology^(3,4,9). It more frequently affects middle-aged patients (between 50 and 70 years) with a certain predominance in the male gender⁽³⁾. Although its etiology is unknown, chronic inflammation of the bile duct secondary to the presence of biliopancreatic reflux, hepatolithiasis and oriental liver fluke infection (endemic in Asia) is considered a probable causal mechanism^(2,9). It is an often asymptomatic condition, being detected incidentally in images or in the study of altered liver function. When symptomatic, they are the result of the development of bile duct obstruction, which leads to biliary colic, jaundice, and sometimes the development of cholangitis^(2,3,9), the risk being higher in the presence of a secretory tumor mucin⁽²⁾. The progression of IPNB to papillary adenocarcinoma has been defined through the adenoma-carcinoma pathway, an invasive component being described in 40 to 80% of reported cases^(2,4).

Yaohong *et al.* in 2015 in their literature review mention a total of 354 cases reported as of the date of publication (52.8% of cases from Japan, 19.5% from other eastern countries such as China, Korea and Taiwan, and 27.7% from western countries such as the United Kingdom, the USA, and Germany), where an average presentation age of 64.6 years (35-80 years) and a male / female ratio of 1,5 are described. Among the clinical manifestations, pain in the right hypochondrium (35-88.5%), recurrent acute cholangitis (5-59%) and obstructive jaundice (20-36%) were the prevalent findings, being asymptomatic in 5% of the cases. Of the 354 patients, 57.5% were located in the left hepatic lobe, 29.5% in the right lobe and 13.4% in other locations including the common hepatic duct⁽⁴⁾. The most frequent histological subtypes found in this study were the pancreatobiliary (41.8%) and the intestinal (28%), with the pancreatobiliary and gastric subtypes being the most invasive⁽⁴⁾. Since then, some reports and case series have been published in the world medical literature (Wang 19 cases, Pérez Saborido 3 cases, among others)^(10,11). In Colombia, Doctor Martín Gómez in 2015 published the first case of intraductal papillary neoplasm of the bile duct⁽¹²⁾.

Regarding the diagnosis of this biliary lesion, imaging studies such as ultrasound and contrast computed tomography (CT) are nonspecific. CT could demonstrate the presence of a hypercapturing biliary focal mass with proximal dilation of the bile duct. Cholangioresonance can show from ductal dilation in the absence of a visible tumor, to a tumor with multiple intraductal papillary projections in the presence of empty areas within the biliary lumen⁽²⁾. Four radiological manifestations of

IPNB have been described that depend on the size and morphology of the intraductal mass: 1) mass with proximal ductal dilation, 2) disproportionate biliary dilation without mass, 3) mass with proximal and distal ductal dilation, and 4) cystic lesions; however, they are not pathognomonic of this condition⁽⁹⁾. In 2018, Lee *et al.* in a retrospective study with 120 patients, found that the findings in cholangioresonance that make it possible to differentiate between IPNB associated with low-grade intraepithelial neoplasia and IPNB associated with invasive carcinoma are: tumor size (≥ 2.5 cm), the presence of multifocal lesions, thickening of the bile duct wall > 3 mm, and invasion of adjacent organs (p value ≤ 0.002)⁽¹³⁾. Tumor markers such as CA 19-9 tend to be higher in patients with mucinous neoplasms compared to simple cysts, however, the serum measurement of this tumor marker does not allow a precise differentiation between benign and malignant tumors. Intracystic measurement of Ca 19-9 is an additional method that aids in differentiating a simple cyst from a mucinous cyst⁽¹⁾. In some case series of patients with IPNB, elevation of Ca 19-9 has been reported in approximately 40%^(10,14). The exit of a mucoid material by the papilla during duodenoscopy, as well as the presence of multiple small, fixed and irregular filling defects in the cholangiography during ERCP, could help in the diagnosis, however, they are not specific to this pathology. In cholangioscopy, papillary projections of disordered and irregular growth that arise from the biliary walls with a dilated bile duct can be identified⁽²⁾. For its part, PET-CT may have a role in differentiating between non-invasive and invasive IPNB and papillary cholangiocarcinoma⁽¹⁵⁾.

Regarding the treatment of these lesions, curative resection with negative margins is the treatment of choice in patients candidates for surgical management without compromise at a distance^(1,4,9,10). Performing intraoperative cholangioscopy could be useful in determining tumor extension, as well as performing a freeze biopsy to determine surgical margins⁽¹⁰⁾. If there is extensive compromise of the bile duct in the presence of positive margins, consideration should be given to resecting the entire biliary tree by means of a liver transplant with pancreatoduodenectomy⁽⁹⁾. In the event that the patient is not a candidate for surgical management, palliative treatment includes chemotherapy, transhepatic percutaneous drainage, endoscopic drainage, laser cholangioscopy ablation, and intraluminal therapy with iridium 192⁽⁴⁾. The median survival rate of patients with IPNB is 62 months, better than that of patients with cholangiocarcinoma⁽⁴⁾.

In conclusion, biliary intraductal papillary neoplasia is an infrequent pathology and requires imaging, associated with cholangioscopy and biopsy by this method, or by ERCP to achieve a conclusive diagnosis, since it can initially be confused with choledocholithiasis.

Statement of Ethics

In accordance with the World Medical Association Declaration of Helsinki, the patient of this case report has given his written informed consent to publish his case, including publication of images.

Declared conflict of interest of all authors: The authors have no conflicts of interest to declare.

REFERENCES

1. Fuente I, Gonzalez M, de Santibañes M, Pekolj J, Mazza O, de Santibañes E, et al. Intraductal Papillary Neoplasm of the Bile Duct (IPNB): Case Report and Literature Review of a Challenging Disease to Diagnose. *J Gastrointest Cancer*. 2019;50(3):578-582.
2. Kohli DR, Shah TU. Board Review Vignette: Intraductal Papillary Neoplasm of the Bile Duct. *Am J Gastroenterol*. 2018;113(5):639-41.
3. Ohtsuka M, Shimizu H, Kato A, Yoshitomi H, Furukawa K, Tsuyuguchi T, et al. Intraductal Papillary Neoplasms of the Bile Duct. *Int J Hepatol*. 2014;2014:459091.
4. Tan Y, Milikowski C, Toribio Y, Singer A, Rojas CP, Garcia-Buitrago MT. Intraductal papillary neoplasm of the bile ducts: A case report and literature review. *World J Gastroenterol*. 2015;21(43):12498-504.
5. Nanashima A, Imamura N, Sumida Y, Hiyoshi M, Hamada T, Nagayasu T. Clinicopathological Aspects and Diagnostic Problems in Patients with Intraductal Papillary Neoplasm of the Bile Duct. *Anticancer Res*. 2018;38(4):2343-52.
6. Chen TC, Nakanuma Y, Zen Y, Chen MF, Jan YY, Yeh T Sen, et al. Intraductal papillary neoplasia of the liver associated with hepatolithiasis. *Hepatology*. 2001;34(4 I):651-8.
7. Zen Y, Fujii T, Itatsu K, Nakamura K, Minato H, Kasashima S, et al. Biliary papillary tumors share pathological features with intraductal papillary mucinous neoplasm of the pancreas. *Hepatology*. 2006;44(5):1333-43.
8. Fléjou J-F. Classification OMS 2010 des tumeurs digestives : la quatrième édition. *Ann Pathol*. 2011;31(5):S27-31.
9. Park HJ, Kim SY, Kim HJ, Lee SS, Hong GS, Byun JH, et al. Intraductal Papillary Neoplasm of the Bile Duct: Clinical, Imaging, and Pathologic Features. 2018;211(1):67-75.
10. Wang X, Cai YQ, Chen YH, Liu XB. Biliary tract intraductal papillary mucinous neoplasm: Report of 19 cases. *World J Gastroenterol*. 2015;21(14):4261-7.
11. Pérez Saborido B, Bailón Cuadrado M, Rodríguez López M, Asensio Díaz E, Madrigal Rubiales B, Barrera Rebollo A. Intraductal papillary neoplasia of the bile duct with malignancy: A differentiated entity of cholangiocarcinoma with a better prognosis, a review of three new cases. *Rev Española Enfermedades Dig*. 2017;109(8):592-5.
12. Gómez M, Riveros J, Otero W. Neoplasia mucinosa papilar de la vía biliar: reporte de caso. *Rev Colomb Gastroenterol*. 2018;30(3):347.
13. Lee S, Kim MJ, Kim S, Choi D, Jang KT, Park YN. Intraductal papillary neoplasm of the bile duct: Assessment of invasive carcinoma and long-term outcomes using MRI. *J Hepatol*. 2019;70(4):692-9.
14. Lee SS, Kim MH, Lee SK, Jang SJ, Song MH, Kim KP, et al. Clinicopathologic Review of 58 Patients with Biliary Papillomatosis. *Cancer*. 2004;100(4):783-93.
15. Ikeno Y, Seo S, Yamamoto G, Nakamoto Y, Uemoto Y, Fuji H, et al. Usefulness of Preoperative 18 F-FDG-PET in Detecting Invasive Intraductal Papillary Neoplasm of the Bile Duct. *Anticancer Res*. 2018;38(6):3677-82.

Correspondence:

Alan Felipe Ovalle Hernández
 Department of Gastroenterology, Hospital Universitario San Ignacio
 Street 45 number 6-24, Bogotá, Colombia
 E-mail: afovalle@javeriana.edu.co