

Endoscopic removal of a toothbrush in a young adult with psychiatric disorder

Extracción endoscópica de un cepillo de dientes en un adulto joven con trastorno psiquiátrico

Claudia Alvizuri-Gómez¹, Jorge Espinoza-Ríos^{1,2}

¹ Department of Gastroenterology, Hospital Nacional Cayetano Heredia. Lima, Peru.

² Professor Faculty of Medicine "Alberto Hurtado", Universidad Peruana Cayetano Heredia. Lima, Peru.

Recibido: 26/07/2021 - Aprobado: 27/09/2021

ORCID: Claudia Alvizuri-Gómez: <https://orcid.org/0000-0003-0833-7997>, Jorge Espinoza-Ríos: <https://orcid.org/0000-0002-9293-8658>

ABSTRACT

Ingestion of foreign bodies is a relative common situation in the emergency department; however, ingestion of toothbrush is rarely reported in the literature. We present the case of a 27-year-old man with a previous diagnosis of obsessive-compulsive disorder, who presented to the emergency department 17 hours after an ingestion of a toothbrush. We performed an endoscopic removal using a polypectomy snare in the Gastroenterology Department under moderate sedation. No complications were reported in the procedure and the patient was discharged few hours later. Ingestion of toothbrush is rare in the literature and some authors described techniques using overtube and retractable snares and forceps. Endoscopic removal of a toothbrush under moderate sedation can be a safe and successful procedure. However, if endoscopic removal fails, surgery should be performed.

Keywords: Foreign bodies; Endoscopy; Obsessive-compulsive disorder (fuente: DeCS BIREME).

RESUMEN

La ingestión de cuerpos extraños es una situación relativamente común en el departamento de emergencias; sin embargo, la ingestión de cepillo de dientes rara vez se informa en la literatura. Presentamos el caso de un varón de 27 años con diagnóstico previo de trastorno obsesivo compulsivo, que acudió al servicio de urgencias 17 horas después de la ingestión de un cepillo de dientes. Realizamos una extirpación endoscópica usando un asa de polipectomía en el Servicio de Gastroenterología bajo sedación moderada. No se reportaron complicaciones en el procedimiento y el paciente fue dado de alta pocas horas después. La ingestión de cepillo de dientes es rara en la literatura y algunos autores describen técnicas que utilizan sobretubo y asas y fórceps retráctiles. La extracción endoscópica de un cepillo de dientes bajo sedación moderada puede ser un procedimiento seguro y exitoso. Sin embargo, si la extracción endoscópica falla, se debe realizar una cirugía.

Palabras clave: Cuerpos extraños; Endoscopia; Trastorno obsesivo compulsivo (source: MeSH NLM).

INTRODUCTION

Foreign bodies in gastrointestinal tract are usually associated to the pediatric population; however, predisposing conditions in some patients can result in occurrence of this medical emergency in adults ⁽¹⁾. Among ingested foreign bodies, the toothbrush is one of the most bizarre due to its length and manipulation of it in order to be ingested. We present the case of a 27-year-old-man who ingested an 18-centimeter-long toothbrush and presented to the emergency department 17 hours later.

CASE REPORT

A 27-year-old man with a previous medical record for obsessive compulsive disorder currently untreated, was admitted to the emergency department 17 hours after an accidental ingestion of a toothbrush while brushing his teeth and palate in an energetic way. Immediately after, he experienced a choking feeling and could not expel the toothbrush even with Heimlich maneuver applied by a relative. After that, the patient swallowed the toothbrush completely and presented drooling but denied dysphagia nor odynophagia.

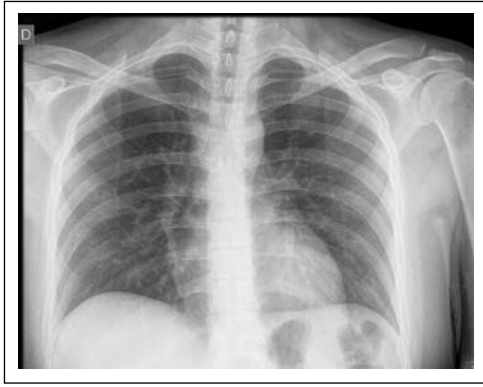


Figure 1. Plain chest X-Ray.

At clinical evaluation, the patient was in a general well-being condition and asymptomatic. No lesions were found in oral cavity and no cutaneous emphysema was identified. Plain neck, chest and abdominal x-ray did not evidence any foreign bodies and were normal as shown in Figure 1. Informed written consent for upper gastrointestinal endoscopy explaining the possible complications was obtained from the patient.

Esophagogastroduodenoscopy was performed in the Gastroenterology Department under moderate sedation with Midazolam, Pethidine and Propofol. The toothbrush handle was found in the distal part of the esophagus and its head (brush) into the gastric cavity toward the greater curvature (Figure 2 and 3). A polypectomy snare was used to hook the handle part of the toothbrush located in the esophagus and pull through the digestive track until it reached the mouth where it was removed by hand. The procedure lasted 8 minutes. Relook endoscopy was performed and evidenced mild erythema in the gastric corpus.

The toothbrush length was 18 centimeters (Figure 4). After the procedure the patient presented no complications and was discharged home along with psychiatric assistance.

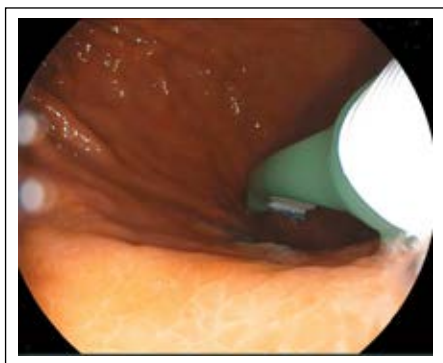

Figure 3. Head of the toothbrush in the greater curvature of the gastric corpus.

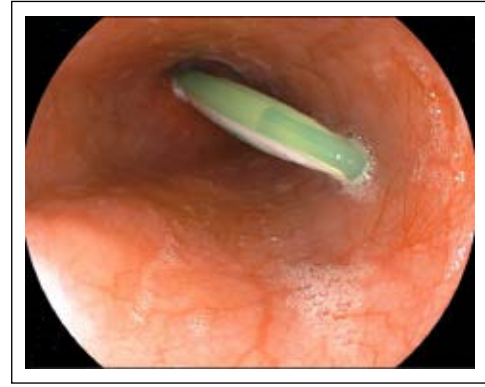

Figure 2. Toothbrush stuck in the lower esophageal sphincter.

DISCUSSION

The presence of a foreign body in the gastrointestinal track is a medical emergency and has to be resolved as soon as possible. Ingestion can be unintentional, but many comorbidities as psychiatric diseases, alcohol, drug addiction or advanced age can be associated ^(2,3).

Timing in which the patient should be intervened for removing the foreign body depends on the object ingested and risk of aspiration. Prolonged time in the gastrointestinal track may lead to mucosal erosions, necrosis and perforation and is recommendable not to exceed 24 hours before removal. In case of our patient, the ingestion of the toothbrush did not allow him to eat and removal was urgent as long objects cannot usually pass the duodenum ⁽⁴⁾.

Radiographic images can help to identify the object ingested or to evaluate the presence of complications such as pneumomediastinum or emphysema ⁽⁵⁾. Up to 34.8% of foreign bodies as food bolus or fish bones cannot be found in radiographic images or endoscopic procedures as spontaneous passage can occur ⁽³⁾. Some studies report that toothbrushes can be identified in plain radiographic images; however, in the case of our



Figure 4. Toothbrush length in centimeters.

patient we were not able to identify any object before the endoscopic procedure ^(6,7).

Ingestion of toothbrush is rare in the literature and few techniques have been described to remove it. Some authors, removed the toothbrush with overtube facilitated endoscopy, retractable snares and forceps ^(2,7,8). The position in which it should be withdrawn depends on the location. If the toothbrush is found in the pylorus, removal from the brush is more feasible ⁽⁹⁾. We decided to remove it from the handle as it was located proximally in the distal esophagus. We were not able to use the overtube due to the position and the size of the toothbrush. However, no complications during the procedure were reported.

A high risk of bleeding or perforation exists ⁽¹⁰⁾. Sewpaul et al, reported a swallowed toothbrush that passed the pylorus but presented later general abdominal tenderness and perforated the ileum ⁽¹¹⁾. If endoscopic therapy fails, surgery should be attempted as there are no possibilities of spontaneous passage due to its length and shape ⁽¹²⁾. Rasheed et al reported an ingestion of toothbrush managed surgically after a failed endoscopic attempt ⁽¹³⁾.

In conclusion, endoscopic removal of a toothbrush under moderate sedation in the Gastroenterology Department can be a safe and successful procedure. However, if endoscopic removal fails, surgery should be performed.

Conflict of interest statement: The authors have no conflicts to declare.

Contribution: CAG drafted the initial manuscript. JER edited and provided final approval of manuscript.

No financial supports were needed for this report.

No prior presentation of this case has been done before.

REFERENCES

1. Hesham A-Kader H. Foreign body ingestion: children like to put objects in their mouth. *World J Pediatr.* 2010;6(4):301-10. doi: 10.1007/s12519-010-0231-y.
2. Harvey M, Cave G, Prince G. Endoscopic removal of an inadvertently swallowed toothbrush in the emergency department. *Case Rep Emerg Med.* 2012;2012:568163. doi: 10.1155/2012/568163.
3. Mosca S, Manes C, Martino R, Amitrano L, Bottino V, Bove A, et al. Endoscopic management of foreign bodies in the upper gastrointestinal tract: report on a series of 414 adult patients. *Endoscopy.* 2001;33(8):692-6. doi: 10.1055/s-2001-16212.
4. Eisen GM, Baron TH, Dominitz JA, Faigel DO, Goldstein JL, Johanson JF, et al. Guideline for the management of ingested foreign bodies. *Gastrointest Endosc.* 2002;55(7):802-6. doi: 10.1016/s0016-5107(02)70407-0.
5. Kim TJ, Goo JM, Moon MH, Im JG, Kim MY. Foreign bodies in the chest: how come they are seen in adults? *Korean J Radiol.* 2001;2(2):87-96. doi: 10.3348/kjr.2001.2.2.87.
6. Tonkic A, Bogdanovic Z, Grandić L. Successful endoscopic removal of a swallowed toothbrush: case report. *Case Rep Gastroenterol.* 2011;5(1):122-4. doi: 10.1159/000326962.
7. Lu XL, Cao HL, Qian KD. Endoscopic removal of an accidentally swallowed toothbrush. *Intern Med.* 2008;47(20):1797-8. doi: 10.2169/internalmedicine.47.0910.
8. Klancnik M, Grgec M, Perković N, Ivanišević P, Poljak NK. A Foreign Body (Toothbrush) in the Esophagus of a Patient with Hiatal Hernia. *Case Rep Gastroenterol.* 2017;11(1):184-189. doi: 10.1159/000464277.
9. Beristain-Hernández JL, Torres-Olalde ME, Rojano-Rodríguez M. Endoscopic retrieval of toothbrushes in a schizophrenic patient. *Rev Esp Enferm Dig.* 2017;109(1):63-64. doi: 10.3748/wjg.14.4410.
10. Chao HH, Chao TC. Perforation of the duodenum by an ingested toothbrush. *World J Gastroenterol.* 2008;14(27):4410-2. doi: 10.3748/wjg.14.4410.
11. Sewpaul A, Shaban F, Venkatasubramaniam AK, Tennant D, Kelly SB. The case of the forgotten toothbrush. *Int J Surg Case Rep.* 2012;3(5):184-5. doi: 10.1016/j.ijscr.2012.01.008.
12. Farahnak MR, Araghi S, Nikakhlagh S, Saki N. Toothbrush: A Report of an Unusual Foreign Body. *Iran J Otorhinolaryngol.* 2015;27(80):247-9.
13. Rasheed MA, Kashif A, Naz A, Ali S. Accidental Ingestion Of Toothbrush: An Unusual Foreign Body. *J Ayub Med Coll Abbottabad.* 2018;30(1):130-132.

Correspondence:

Claudia Alvarez-Gómez
 Department of Gastroenterology, Hospital Nacional Cayetano Heredia
 Honorio Delgado 262, San Martín de Porres, Lima 15102 - Peru
 E-mail: claudia.alvizuri@upch.pe