

## A review on endoscopic palliation of obstructive jaundice before surgery

Una revisión de la paliación endoscópica de la ictericia obstructiva antes de la cirugía

Everson L.A. Artifon<sup>1,2</sup>, Jose P. Otoch<sup>3</sup>, Asadur J. Tchekmedyan<sup>4,5</sup>

<sup>1</sup> Servicio de Endoscopia. Hospital Ana Costa. Santos, San Pablo, Brasil.

<sup>2</sup> Sector de Endoscopia Biliopancreática (CPRE), Servicio de Endoscopia, Hospital de Clínicas. Facultad de Medicina, Universidad de San Pablo. San Pablo, Brasil.

<sup>3</sup> Departamento de Cirugía, Universidad de San Pablo, San Pablo, Brasil.

<sup>4</sup> Hospital Pasteur, Ministerio de Salud Pública. Montevideo, Uruguay.

<sup>5</sup> Sociedad de Gastroenterología del Uruguay. Montevideo, Uruguay.

Recibido: 17-03-2014; Aprobado: 02-06-2014

### ABSTRACT

Since its development, endoscopic retrograde cholangiopancreatography (ERCP) has evolved from a simple diagnostic technique to an important therapeutic procedure. Obstructive jaundice is often the first and most common complication in patients with malignant disease of the extrahepatic biliary tract. Although preoperative biliary drainage (PBD) may be instituted in many centers, different studies have reported divergent results regarding its benefits in reducing the complications of hepatopancreatobiliary surgery, especially with regard to pancreatoduodenectomy for pancreatic cancer. In this review, we will summarize the current literature of PBD and describe its indications, possible benefits, and, when indicated, the appropriate interval before surgery.

**Key words:** Cholangiopancreatography, endoscopic retrograde; Pancreatic neoplasms; Cholangiocarcinoma (source: MeSH NLM).

### RESUMEN

Desde su desarrollo, la colangiopancreatografía retrógrada endoscópica ha evolucionado de una técnica puramente diagnóstica a un procedimiento netamente terapéutico. La ictericia obstructiva es a menudo la primera y más común de las complicaciones en los pacientes con enfermedad maligna de la vía biliar extrahepática. Aunque el drenaje biliar preoperatorio (DBP) puede ser realizado en múltiples centros, diferentes estudios han reportado resultados divergentes con respecto a sus beneficios en la reducción de las complicaciones de la cirugía biliopancreática, especialmente con respecto a duodenopancreatectomía para el cáncer de páncreas. En esta revisión, resumimos la literatura actual del DBP y describimos sus indicaciones, posibles beneficios y cuando esté indicado, el intervalo apropiado antes de la cirugía.

**Palabras clave:** Pancreatocolangiografía retrógrada endoscópica; Cáncer de páncreas; Colangiocarcinoma (fuente: DeCS BIREME).

### INTRODUCTION

Obstructive jaundice is the presenting symptom in up to 90% of the patients with malignant disease that involves the extrahepatic biliary tract<sup>(1)</sup>. The hyperbilirubinemia due to biliary obstruction can lead to hepatic dysfunction, impairment of digestion and absorption of fat and liposoluble vitamins, coagulopathy, immunodeficiency, biliary infection and endotoxemia, nephropathy, and, at the end stage, liver failure and hepatorenal syndrome<sup>(2)</sup>.

The most common malignant diseases related to the extrahepatic distal or proximal biliary tract are pancreatic cancer and cholangiocarcinoma. The only potentially curative option is radical resection of the tumor, where pancreatic head tumors and distal cholangiocarcinomas are managed by pancreatoduodenectomy; while proximal or hilar

(Klatskin) extrahepatic cholangiocarcinomas affecting the common bile duct are managed with hilar resection with partial hepatectomy if indicated<sup>(1)</sup>.

It has been observed that postoperative mortality after hepatopancreatobiliary surgery decreased from 20% to less than 5% in high-volume centers; however, the morbidity remains high at 40% to 60% (3,4). Since surgery in patients with jaundice is thought to increase the risk of postoperative complications, preoperative biliary drainage (PBD) was introduced to improve the postoperative outcome<sup>(5)</sup>.

In 1935, Whipple et al. first proposed a two-staged surgical procedure with PBD to relieve obstructive jaundice before pancreaticoduodenectomy<sup>(6)</sup>, in order to reduce morbidity and mortality in patients who underwent surgery for pancreatic cancer. Since then, non-surgical techniques, such as percutaneous

Citar como: Artifon ELA, Otoch JP, Tchekmedyan AJ. A review on endoscopic palliation of obstructive jaundice before surgery. Rev Gastroenterol Peru. 2014;34(3):225-8.

transhepatic cholangiography (PTC) to place external-internal biliary drains and endoscopic retrograde cholangiopancreatography (ERCP) to place biliary stents, became available in clinical practice. Nowadays, these techniques are the most used for PBD, with ERCP being the preferred method for distal obstruction and PTC generally used in proximal biliary obstruction.

Although PBD clinical practice may be instituted in many centers, different studies have reported divergent results regarding its benefits in reducing the complications of hepatopancreatobiliary surgery, especially when regarded to pancreatoduodenectomy for pancreatic cancer.

In this article, we will synthesize the current literature of PBD and describe its indications, possible benefits, and, when indicated, the appropriate interval before surgery. We divided the discussion into four areas:

1. Advantages of PBD
2. Disadvantages of PBD
3. PBD before Pancreatoduodenectomy
4. PBD before Partial Hepatectomy

## 1. ADVANTAGES OF PBD

Biliary obstruction is historically regarded as the main factor that worsened hepatobiliary surgical outcomes; therefore, the main reason to pursue PBD is to reduce post-surgical complications. In experimental studies, the three primary insults caused by biliary obstruction were bile extravasation within the hepatic parenchyma; reduced portal blood flow brought about by mechanical compression, and diminished secretion of bile salts into the small bowel <sup>(7)</sup>.

Obstructive jaundice is also associated with portal and systemic endotoxemia, thought to be caused by the absence of bile in the intestinal lumen predisposing to bacterial translocation in addition to dysfunction of Kupffer cells in the liver, which reduces clearance of endotoxins and impairs intracellular bacterial killing <sup>(8)</sup>. In this setting, endotoxemia and bacterial translocation lead to increased levels of proinflammatory cytokines, such as interleukin-6 and tumor necrosis factor <sup>(7)</sup>.

In a recent study, it was observed that, instead of high risk of bleeding due to an impaired synthesis effect in vitamin K-dependent coagulation factors, patients with severe biliary obstruction (bilirubin greater than 10 mg/dL) might have a procoagulant state <sup>(9)</sup>. Bile constituents such as bilirubin, cholesterol, and bile acids do not seem to be nephrotoxic; however, cholestasis has deleterious effects on blood volume and cardiovascular function, which lead to hypotension and impaired

vascular reactivity. These in turn predispose the patient to acute kidney injury via both prerenal azotemia and acute tubular necrosis <sup>(7)</sup>.

Thus, biliary drainage is a therapeutic method that can reduce postoperative septic complications. This concept has been validated in multiple experimental models of biliary drainage resulting in improved overall immune response via improvements in liver function, nutritional status and cell-mediated immune function, and reductions in systemic endotoxemia and cytokine release <sup>(1)</sup>. Based on these facts, it may be hypothesized that PBD can reverse the adverse factors of biliary obstruction and improve the outcome after hepatopancreatobiliary surgeries.

## 2. DISADVANTAGES OF PBD

Important disadvantages of PBD are procedural complications such as bleeding, perforation, stent occlusion and infection.

In animal studies, biliary drainage with stents resulted in chronic inflammation of the bile duct and bile contamination <sup>(10)</sup>. The inserted biliary stents led to thickening of the bile duct wall in both the normal and obstructed segments, causing transmural fibrosis and inflammation. Bacterobilia and bile duct inflammation persisted even after two months of the stent removal.

Biliary obstruction favors biliary bacterial colonization; however PBD is associated with polymicrobial bacterial flora such as *Enterococcus* species, which are found more commonly in bile from patients with prior stent placement <sup>(7)</sup>. In fact, an association between PBD, biliary contamination, and postoperative complication rate has been described. In one study, PBD was significantly associated with bile infection, and bile infection increased the overall rates of infective complications and renal insufficiency <sup>(7)</sup>.

With regard to PBD for pancreatic cancer, different studies have not shown any significant benefits after the procedure; in some cases, an increased mortality rate patient who has undergone PBD has been observed <sup>(2)</sup>. In a multicenter, randomized trial, van der Gaag et al. compared PBD with surgery alone for patients with cancer of the pancreatic head, in which the biliary drainage was attempted primarily with the placement of an endoprosthesis by means of ERCP. This study demonstrated that PBD in patients undergoing surgery for cancer of the pancreatic head increased the rate of complications <sup>(5)</sup>.

### 3. PBD BEFORE PANCREATODUODENECTOMY

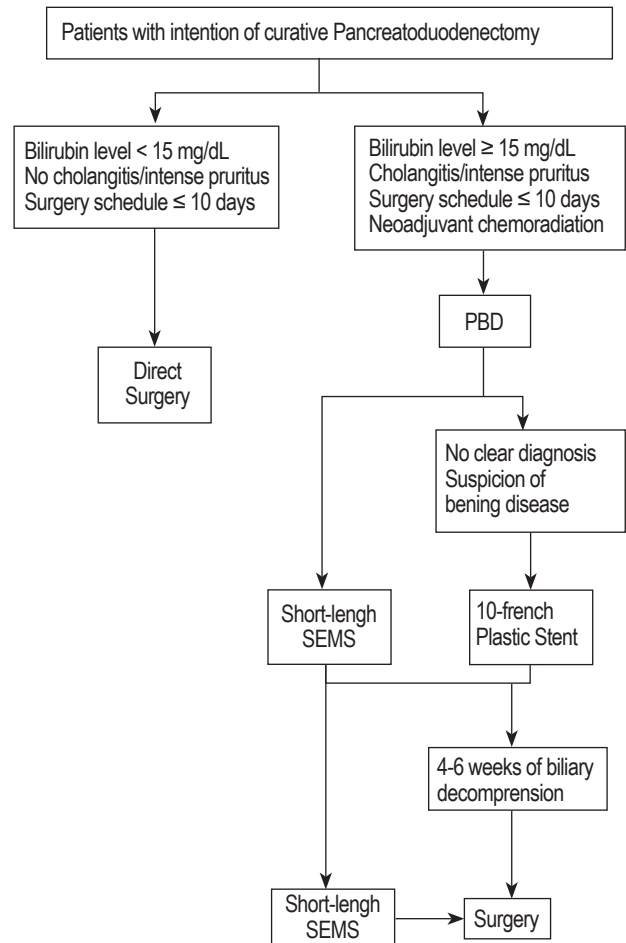
The majority of patients with peri-ampullary malignancies develop symptomatic obstructive jaundice. If these patients do not present with radiological evidence of unresectability, they will undergo exploratory laparotomy or laparoscopy with the intention to resect the tumor if possible <sup>(1)</sup>.

PBD for pancreatic cancer is a common practice among general surgeons worldwide, and, indeed, it should reduce postoperative complications in jaundiced patients because of beneficial effects of biliary decompression. It allows restoration of bile into the normal enterohepatic circulation by means of an internal stent with significant reduction of endotoxemia, and both liver and kidney dysfunction <sup>(8)</sup>.

However, PBD has been questioned over the last decade. Recent systematic reviews and meta-analyses have failed to demonstrate benefits of PBD, even in patients with other pancreatobiliary malignancies, who underwent PBD by percutaneous techniques or ERCP. As mentioned earlier, a large randomized controlled trial addressed the question of whether jaundiced patients with resectable pancreatic cancer should undergo PBD <sup>(5)</sup>. This study demonstrated that PBD increases postoperative complication rate in jaundiced patients undergoing pancreaticoduodenectomy for cancer and that direct, immediate (within 7-10 days from the diagnosis) surgery is the best approach for the treatment of these patients. Several criticisms have been risen about this study. Even though the study's conclusions are not definitive, its findings had a major implication for clinical practice.

Therefore, PBD should be indicated in jaundiced patients with acute cholangitis, bilirubin levels higher than 15 mg/dL, severe pruritus, or if a delay of surgery is expected (eg in the setting of neoadjuvant chemoradiation). In these cases, preoperative ERCP with the placement of metal biliary stents should be preferred over plastic stents in such patients <sup>(11)</sup>. It is believed that self-expandable metallic stents might have a longer patency and fewer stent related problems, and short stents (4 to 6 cm) could be removed with the surgical specimen.

Nevertheless, the debate about PBD for jaundiced patients with potentially curative peri-ampullary malignancies is far from over. Despite recent data against its indications, PBD will continue to be performed in selected cases. In a review article, de Bellis et al. proposed a rational algorithm for the management of jaundiced patients with resectable pancreatic cancer <sup>(8)</sup>, and, with some small variation, we describe this algorithm in Figure 1.



**Figure 1:** Proposed algorithm for the management of jaundiced patients with intention of curative pancreatoduodenectomy; PBD: Preoperative Biliary Drainage; SEMS: Self-expandable Metallic Stents.

Modified from: de Bellis et al., *Current Drug Target*, 2012, 13, page 760.

### 4. PBD BEFORE PARTIAL HEPATECTOMY

As mentioned earlier, hilar resection with partial hepatectomy is the curative surgery indicated for proximal or hilar (Klatskin) extrahepatic cholangiocarcinomas affecting the common bile duct. Jaundice in perihilar cholangiocarcinoma has distinctive peculiarities when compared with patients that are candidates for pancreatoduodenectomy. In these patients, postoperative mortality is still high, nearly 10% and the cause of death is mainly hepatic failure <sup>(2)</sup>.

PBD was introduced with the aim of reducing potential complications in patients with jaundice secondary to perihilar cholangiocarcinoma. Animal studies are convincing in PBD benefits, meanwhile clinical studies report conflicting results <sup>(1)</sup>. Based on these results, there is currently no consensus on the use of PBD in jaundiced patients with perihilar cholangiocarcinoma undergoing liver resection.

There are concerns that PBD may be associated with an increased incidence of postoperative morbidity and mortality<sup>(12)</sup>, although it has been shown that PBD reverses cholestasis-associated hepatic and systemic toxicity, and improves liver function, nutritional status and cell-mediated immune function. In a recent multicenter European study, overall morbidity was not affected by PBD in patients that underwent major liver resection for perihilar cholangiocarcinoma<sup>(13)</sup>. A change in PBD strategy was suggested for patients that required preoperative portal vein embolization for the treatment of postoperative inadequate residual liver volume and induction of hypertrophy of the future remnant liver<sup>(14)</sup>. Furthermore, PBD followed by portal vein embolization prior to hepatectomy is considered a safe management strategy, particularly in patients with remnant liver volume less than 40%.

Once indicated, another concern about PBD is the technique used, as well as which part of the liver should be drained. The current techniques used for drainage are ERCP, PTC, and nasobiliary. Despite recent studies reporting advantages of nasobiliary over ERCP and PTC techniques<sup>(15)</sup>, external drainage by PTC is traditionally the preferred method for relief of obstructive jaundice due to proximal obstruction. As for the part of the liver that should be drained, a proposed approach is the selective biliary drainage of the remnant liver<sup>(1)</sup>. However, there are no clinical randomized controlled trials regarding the most optimal route of drainage in terms of complication reduction and patient morbidity. It is suggested that the preferred technique for PBD before partial hepatectomy should depend on local expertise.

## FINAL COMMENTS

PBD demonstrates beneficial effects in animal studies. However, several reports demonstrate conflicted results in human studies.

For patients who will undergo pancreatoduodenectomy, PBD should not be routinely performed. PBD should be recommended in patients with severe hyperbilirubinemia, cholangitis, intense pruritus, neoadjuvant chemotherapy or when a delay in surgery is expected to be greater than 10 days from the day of diagnosis. Endoscopic drainage by ERCP with the use of short-length metallic stents should be preferred over PTC, with the latter only undertaken in cases of ERCP failure.

For patients who will undergo partial hepatectomy, PBD should be applied in the majority of the cases. When portal vein embolization is applied, selective biliary drainage should be performed in the future remnant liver. No clinical randomized controlled trial has been performed to define the preferred route of drainage. Therefore, in spite of the presumed advantages of PTC, the preferred technique for PBD should depend on local expertise.

Large multicenter randomized trials are necessary to clarify the usefulness of PBD in hepatopancreatobiliary surgery. For this reason, PBD in jaundiced patients must be a multidisciplinary decision (oncologist, gastroenterologist, radiologist, biliary endoscopist and surgeon) based on the site of the obstruction and the intent a curative surgery.

## REFERENCES

- van der Gaag NA, Kloek JJ, de Castro SM, Busch OR, van Gulik TM, Gouma DJ. [Preoperative biliary drainage in patients with obstructive jaundice: history and current status](#). *J Gastrointest Surg.* 2009 Apr;13(4):814-20. doi: 10.1007/s11605-008-0618-4.
- Iacono C, Ruzzenente A, Campagnaro T, Bortolasi L, Valdegamberi A, Guglielmi A. [Role of preoperative biliary drainage in jaundiced patients who are candidates for pancreatoduodenectomy or hepatic resection: highlights and drawbacks](#). *Ann Surg.* 2013 Feb;257(2):191-204. doi: 10.1097/SLA.0b013e31826f4b0e.
- Gouma DJ, van Geenen RC, van Gulik TM, de Haan RJ, de Wit LT, Busch OR, et al. [Rates of complications and death after pancreaticoduodenectomy: risk factors and the impact of hospital volume](#). *Ann Surg.* 2000 Dec;232(6):786-95.
- Dindo D, Demartines N, Clavien PA. [Classification of surgical complications: a new proposal with evaluation in a cohort of 6336 patients and results of a survey](#). *Ann Surg.* 2004 Aug;240(2):205-13.
- van der Gaag NA, Rauws EA, van Eijck CH, Bruno MJ, van der Harst E, Kubben FJ, et al. [Preoperative biliary drainage for cancer of the head of the pancreas](#). *N Engl J Med.* 2010 Jan 14;362(2):129-37. doi: 10.1056/NEJMoa0903230.
- Whipple AO, Parsons WB, Mullins CR. [Treatment of carcinoma of the ampulla of Vater](#). *Ann Surg.* 1935 Oct;102(4):763-79.
- Bonin EA, Baron TH. [Preoperative biliary stents in pancreatic cancer](#). *J Hepatobiliary Pancreat Sci.* 2011 Sep;18(5):621-9. doi: 10.1007/s00534-011-0403-8.
- de Bellis M, Palaia R, Sandomenico C, Di Girolamo E, Cascella M, Fiore F. [Is preoperative endoscopic biliary drainage indicated for jaundiced patients with resectable pancreatic cancer?](#) *Curr Drug Targets.* 2012 Jun;13(6):753-63.
- Kloek JJ, Heger M, van der Gaag NA, Beuers U, van Gulik TM, Gouma DJ, et al. [Effect of preoperative biliary drainage on coagulation and fibrinolysis in severe obstructive cholestasis](#). *J Clin Gastroenterol.* 2010 Oct;44(9):646-52. doi: 10.1097/MCG.0b013e3181ce5b36.
- Karsten TM, Davids PH, van Gulik TM, Bosma A, Tytgat GN, Klopper PJ, et al. [Effects of biliary endoprosthesis on the extrahepatic bile ducts in relation to subsequent operation of the biliary tract](#). *J Am Coll Surg.* 1994 Apr;178(4):343-52.
- Baron TH, Kozarek RA. [Preoperative biliary stents in pancreatic cancer--proceed with caution](#). *N Engl J Med.* 2010 Jan 14;362(2):170-2. doi: 10.1056/NEJMe0908773.
- Xiong JJ, Nunes QM, Huang W, Pathak S, Wei AL, Tan CL, et al. [Preoperative biliary drainage in patients with hilar cholangiocarcinoma undergoing major hepatectomy](#). *World J Gastroenterol.* 2013 Dec 14;19(46):8731-9. doi: 10.3748/wjg.v19.i46.8731.
- Farges O, Regimbeau JM, Fuks D, Le Treut YP, Cherqui D, Bachellier P, et al. [Multicentre European study of preoperative biliary drainage for hilar cholangiocarcinoma](#). *Br J Surg.* 2013 Jan;100(2):274-83. doi: 10.1002/bjs.8950.
- Maguchi H, Takahashi K, Katanuma A, Osanai M, Nakahara K, Matuzaki S, et al. [Preoperative biliary drainage for hilar cholangiocarcinoma](#). *J Hepatobiliary Pancreat Surg.* 2007;14(5):441-6.
- Kawashima H, Itoh A, Ohno E, Itoh Y, Ebata T, Nagino M, et al. [Preoperative endoscopic nasobiliary drainage in 164 consecutive patients with suspected perihilar cholangiocarcinoma: a retrospective study of efficacy and risk factors related to complications](#). *Ann Surg.* 2013 Jan;257(1):121-7. doi: 10.1097/SLA.0b013e318262b2e9.

## Correspondence:

Asadur Jorge Tchekmedyan  
 Rambla República del Perú 1413 – Ap. 201. Montevideo 11300.  
 Uruguay  
 E-mail: [asadur@adinet.com.uy](mailto:asadur@adinet.com.uy)