

## REPORTE DE CASO

# Management of refractory hepatic hydrothorax: a report of two cases and review of the literature

## Manejo de hidrotórax hepático refractario: reporte de dos casos y revisión de la literatura

Lesly Calixto-Aguilar<sup>1</sup> , Javier Díaz Ferrer<sup>2,3,4</sup> 

<sup>1</sup> Clínica Médica Cayetano Heredia. Lima, Peru.

<sup>2</sup> Department of Gastroenterology, Hospital Nacional Edgardo Rebagliati Martins. Lima, Peru.

<sup>3</sup> Clínica Internacional. Lima, Peru.

<sup>4</sup> Faculty of Medicine, Universidad de San Martín de Porres. Lima, Peru.

**Received:** 21/08/2023  
**Approved:** 03/03/2024  
**Online:** 26/06/2024

### Author contribution

LCA: wrote the manuscript. LCA, JDF: reviewed the literature and edited the manuscript. All authors approved the final version.

### Conflicts of interest

The authors have no potential conflicts of interest.

### Funding

No funding.

### Cite as

Calixto-Aguilar L, Díaz Ferrer J. Management of refractory hepatic hydrothorax: a report of two cases and review of the literature. *Rev Gastroenterol Peru.* 2024;44(2):155-8. doi: 10.47892/rgp.2024.442.1595

### ABSTRACT

Hepatic hydrothorax is a transudative pleural effusion in patients with cirrhosis. A 56-year-old cirrhotic patient presented with dyspnea and desaturation; his chest images showed a right pleural effusion. Another 66-year-old woman with cirrhosis, developed during her hospitalization acute respiratory failure, and her chest X-ray showed left pleural effusion. Initially, both patients were prescribed a dietary sodium restriction and diuretics. Nevertheless, they didn't have a good response so a chest tube was placed, and an octreotide infusion partially reduced the volume of the pleural drainage allowing a pleurodesis. We report two cases of refractory hepatic hydrothorax with multiple treatments including octreotide and pleurodesis.

**Keywords:** Liver cirrhosis; Hydrothorax; Octreotide; Pleurodesis (source: MeSH NLM).

### RESUMEN

El hidrotórax hepático se define como una efusión pleural de tipo trasudado en pacientes con cirrosis hepática. Un paciente cirrótico de 56 años se presentó a nuestro servicio de emergencias con disnea y desaturación. La radiografía de tórax reveló una efusión pleural derecha. Otra paciente de 66 años, también diagnosticada con cirrosis, desarrolló insuficiencia respiratoria aguda durante su hospitalización, presentando una efusión pleural izquierda en la radiografía de tórax. Inicialmente, ambos pacientes fueron sometidos a una dieta hiposódica y se les administraron diuréticos. Sin embargo, debido a la falta de respuesta adecuada, se les colocó un tubo de drenaje torácico y se les administró una infusión de octreótide, lo cual redujo parcialmente el volumen pleural y permitió la realización posterior de una pleurodesis. Presentamos dos casos de hidrotórax hepático refractario tratados con múltiples intervenciones terapéuticas.

**Palabras clave:** Cirrosis hepática; Hidrotórax; Octreótide; Pleurodesia (fuente: DeCS Bireme).

### INTRODUCTION

Hepatic hydrothorax (HH) is a transudative pleural effusion in patients with cirrhosis without any cardiac, pulmonary or renal disease. It has a significant morbidity and mortality, with a median survival of 8 to 12 months <sup>(1)</sup>. The clinical manifestations include shortness of breath, cough, hypoxemia, and chest pain <sup>(2)</sup>. The first line of treatment includes restricting sodium intake and administration of diuretics. But 20-27% of patients will develop refractory hydrothorax <sup>(3,4)</sup>. Refractory HH is defined as pleural effusion that failed to respond to strict salt diet, maximum dose of diuretics and more than two thoracentesis or patients with pleural effusion that reappeared after therapeutic thoracentesis <sup>(5)</sup>. Multiple therapeutic options include thoracentesis, indwelling pleural catheter placement, pleurodesis with repair diaphragmatic defects using video-assisted thoracoscopy surgery, transjugular intrahepatic portosystemic shunts (TIPS), liver transplantation and use of vasoconstrictors <sup>(4,6)</sup>. We report management of two cases of refractory HH in a tertiary referral hospital in Lima, Peru.

### Correspondence:

Lesly Calixto Aguilar  
Department of Gastroenterology,  
Clínica Médica Cayetano Heredia,  
Lima, Perú.  
Phone number: +51 2076200  
E-mail: lesly.calixto.a@upch.pe

## CASES REPORT

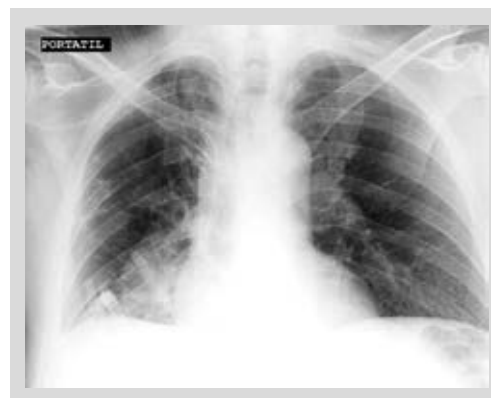### Case 1

A 56-year-old man with history of diabetes mellitus and cirrhosis, presented to the emergency with dyspnea and desaturation. At admission vitals were BP=95/60 mmHg, HR=90, RR=28 and  $SO_2=90\%$  on room air. Physical evaluation revealed respiratory distress, jaundice and absent breath sounds in the 2/3 lower of the right hemithorax. On abdomen, collateral circulation was observed, without distension. Blood tests showed WBC:  $8.13 \times 10^3$  cells/mm<sup>3</sup>, Platelets: 65 000, Hb: 14.4. Liver tests showed Alb: 3.6 g/dl, AST: 85 U/l, ALT: 45 U/l, BiT: 4.16 mg/dl. On further evaluation, a chest X- ray and computed tomography showed a massive right pleural effusion (Figure 1) and portal cavernoma. A therapeutic thoracentesis was performed and a serohematic liquid was noted (1500cc). The samples confirmed a transudative effusion.

A salt-restricted diet, furosemide 40 mg/d, and spironolactone 100 mg/d with an increase up to double doses treatment was implemented; however, the patient presented renal failure. Patient persisted with symptoms, so a chest tube was placed. He underwent a talc pleurodesis, but thoracic drains remained high. Octreotide infusion was started at a dose of 25 ug/d on the first day, 50 ug/h on the second day and 100 ug/h for next two weeks evidencing a decrease in drainage from 2300 cc to 1000 cc. The patient had persistent fever, so the thoracic drainage was removed, and he received meropenem 1 g/8h for 10 days. A second pleurodesis with iodine was performed; and the patient did not present pleural effusion again (Figure 2); however, he developed refractory ascites to diuretics. The patient was admitted to the liver transplant list as an exception to MELD and was discharged with appointments for the institution's paracentesis program. A month later he received a hepatic transplant; unfortunately, the patient died due to hepatic artery thrombosis.

### Case 2

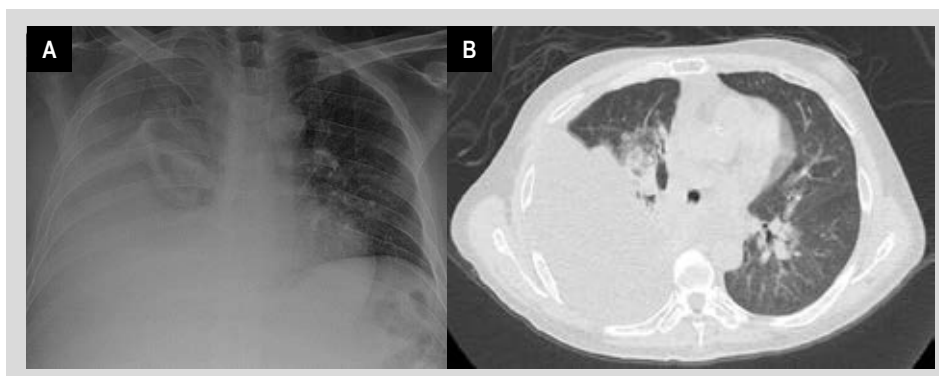
A 66-year-old-woman with previous history of obesity and cirrhosis, came to the emergency room with fever and cellulite in her lower limbs. At admission vitals were



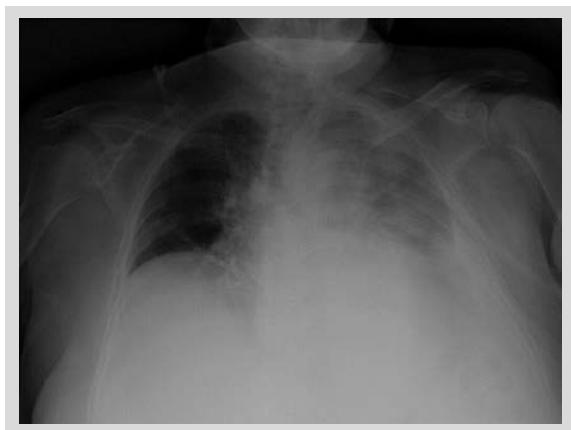
**Figure 2.** Chest X-ray posterior to octreotide infusion and pleurodesis in the first patient.

BP=100/60 mmHg, HR=98, RR=18 and  $SO_2=97\%$  on room air. A physical evaluation revealed encephalopathy II°, increased volume and redness of lower limbs, and abdominal distension. Blood tests showed WBC:  $5.59 \times 10^3$  cells/mm<sup>3</sup>, platelets 52 000, Hb: 8.9. Liver tests showed Alb: 2.1 g/dl, AST: 21 U/l, ALT: 10 U/l, BiT: 3.24 mg/dl. During hospitalization, the patient developed acute respiratory failure with dyspnea and desaturation (86%) on room air. A chest X- ray evidenced left pleural effusion (Figure 3).

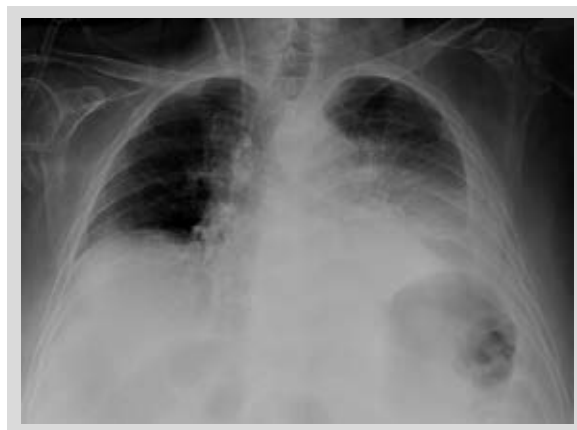A thoracentesis was performed and showed a transudative liquid. The patient received a maximum dose of 120 mg/d of furosemide and 300 mg/d spironolactone. However, she developed acute renal injury without remission with albumin, so a chest tube drainage was placed. Also, we decided to initiate octreotide infusion, it was administered at a dose of 25 ug/h on the first day, 50 ug/h on the second day and 100 ug/h for next 10 days. Pleural effusion was reduced from 1500 cc to 800 cc (Figure 4) and thoracic drainage withdrawal and pleurodesis with iodine were indicated. Unfortunately, the patient developed a complicated urinary tract infection with acute chronic liver failure, which produced her death.



**Figure 1.** Massive right pleural effusion in (A) chest X-ray and (B) chest tomography of the first patient at admission.



**Figure 3.** Left pleural effusion in chest X-ray of the second patient when she developed acute respiratory failure during hospitalization.



**Figure 4.** Chest X-ray posterior to octreotide infusion in the second patient.

### Ethics aspects

Informed consents were obtained for this case report. All the information was anonymous and there is no type of information in the text or images that would allow patients' identification.

## DISCUSSION

The first step of management of HH involves a strict diet plan involving low sodium diet (<2 gr per day). Most patients also need furosemide and spironolactone with increase in a stepwise manner by doubling the dose <sup>(7)</sup>. Our patients followed a strict diet but could not progress to maximum doses of diuretics (spironolactone at 400 mg/day and furosemide at 160 mg/day) because they developed acute renal injury <sup>(5)</sup>.

Nevertheless, when a patient is extremely dyspneic, as in our first case, we should consider first a therapeutic thoracentesis, since this procedure provide rapid relief of symptoms <sup>(2)</sup>. Also, both patients underwent to a chest tube drainage, but they were removed due to infection complications. Maybe we should perform other strategies instead of chest tube placement. According to literature, it is discouraged due to the associated high mortality (12-100%) and morbidity rates (80-100%), with complications that include secondary infection, pneumothorax, hemothorax and acute kidney injury <sup>(5,8)</sup>.

The pleurodesis is a procedure in which the space between the parietal and visceral pleura is obliterated using chemical agents or mechanical procedures to induce fibrosis and prevent recurrent effusion <sup>(9)</sup>. It can be considered in selected patients who are not candidates for TIPS or who are refractory to TIPS and can serve as a bridge to liver transplant. Previous studies showed heterogenous results about pleurodesis and some of them had another concomitant strategy <sup>(10)</sup>. The first pleurodesis with talc in our first patient was not effective; but the second one was successful.

Liver transplant is still the treatment of choice for refractory HH conferring survival advantage over supportive management <sup>(3)</sup>. The patients who are not candidates for a transplant and who are in the waiting list, require a stepwise approach and their treatment should alleviate their symptoms <sup>(6)</sup>. In these patients, TIPS remains as an available option with a success rate of 40 to 79% <sup>(11)</sup>. It decreases the portal pressure, preventing fluid accumulation in the peritoneal and pleural cavities <sup>(8)</sup>. TIPS were not indicated in our patients because of portal cavernoma and persistent encephalopathy. Also, use of vasoconstrictor agents have been described, they reduce splanchnic blood flow and portosystemic pressure gradient, increasing blood pressure, improving renal perfusion and sodium renal excretion <sup>(12-14)</sup>. Octreotide infusion has been reported in some studies with a good treatment response <sup>(15)</sup>, but other cases reported that can cause pulmonary and cardiac side-effects <sup>(10)</sup>. In our patients, there was more than 50% volume reduction in pleural drainage, which allowed a posterior pleurodesis. But it seems there is a maximum point of benefit with the highest dose reported <sup>(4)</sup>.

Further studies are needed to evaluate splanchnic and peripheral vasoconstrictors in the management of HH. We present two cases of refractory HH with multiple approaches of management including octreotide infusion and pleurodesis.

## REFERENCES

1. Pippard B, Bhatnagar M, McNeill L, Donnelly M, Frew K, Au-jayeb A. Hepatic hydrothorax: A Narrative Review. *Pulm Ther.* 2022;8:241-254. doi: 10.1007/s41030-022-00195-8.
2. Kinasewitz G, Keddisi J. Hepatic hydrothorax. *Current Opinion in Pulmonary Medicine.* 2003;9:261-5. doi: 10.1097/00063198-200307000-00003.
3. Porcel JM, Mas E, Reñé JM, Bielsa S. Hidrotórax de causa hepática: análisis de 77 pacientes. *Med Clínica.* 2013;141(11):484-6. doi: 10.1016/j.medcli.2013.06.017.
4. Porcel JM. Management of refractory hepatic hydrothorax. *Curr Opin Pulm Med.* 2014;20(4):352-7. doi: 10.1097/MCP.0000000000000058.

5. Yoon JH, Kim HJ, Jun CH, Cho SB, Jung Y, Choi SK. Various Treatment Modalities in Hepatic Hydrothorax: What Is Safe and Effective? *Yonsei Med J.* 2019;60(10):944-951. doi: 10.3349/ymj.2019.60.10.944.
6. Krok K, Cárdenas A. Hepatic Hydrothorax. *Semin Respir Crit Care Med.* 2012;33(1):3-10. doi: 10.1055/s-0032-1301729.
7. Singh A, Bajwa A, Shujaat A. Evidence-Based Review of the Management of Hepatic Hydrothorax. *Respiration.* 2013;86(2):155-73. doi: 10.1159/000346996.
8. Chaaban T, Kanj N, Bou Akl I. Hepatic Hydrothorax: An Updated Review on a Challenging Disease. *Lung.* 2019;197(4):399-405. doi: 10.1007/s00408-019-00231-6.
9. Assouad J, Le Pimpec Barthes F, Shaker W, Souilamas R, Riquet M. Recurrent pleural effusion complicating liver cirrhosis. *Ann Thorac Surg.* 2003;75(3):986-9. doi: 10.1016/s0003-4975(02)04548-4.
10. Banini BA, Alwatari Y, Stovall M, Ogden N, Gershman E, Shah RD, *et al.* Multidisciplinary Management of Hepatic Hydrothorax in 2020: An Evidence-Based Review and Guidance. *Hepatology.* 2020;72(5):1851-1863. doi: 10.1002/hep.31434.
11. Campos S, Gomes D, Sofia C. Transjugular intrahepatic portosystemic shunt in refractory hydrothorax – a contribution to an unexplored indication: *Eur J Gastroenterol Hepatol.* 2016;28(6):661-6. doi: 10.1097/MEG.0000000000000623.
12. Pfammatter R, Quattropani C, Reichen J, Göke B, Wagner ACC. Treatment of hepatic hydrothorax and reduction of chest tube output with octreotide: *Eur J Gastroenterol Hepatol.* 2001;13(8):977-80. doi: 10.1097/00042737-200108000-00019.
13. Dumortier J, Lepretre J, Scalone O, Boillot O, Scoazec J, Delafosse B, *et al.* Successful treatment of hepatic hydrothorax with octreotide. *European Journal of Gastroenterology & Hepatology.* 2000;12(7):817-20. doi: 10.1097/00042737-200012070-00018.
14. Ibrisić D, Cakaloglu Y, Akyuz F, Karadag A, Ozdil S, Besisik F, *et al.* Treatment of hepatic hydrothorax with terlipressin in a cirrhotic patient. *Scand J Gastroenterol.* 2006;41(7):862-5. doi: 10.1080/00365520500527441.
15. Barreales M, Sáenz-López S, Igarzabal A, Muñoz-Yagüe T, Casis B, Alonso-Navas F, *et al.* Refractory hepatic hydrothorax: successful treatment with octreotide. *Rev Esp Enfermedades Dig.* 2005;97(11):830-5.