

## ***EUS-Guided Access to Dorsal Pancreatic Duct in a Patient with Pancreas Divisum***

Everson L. A. Artifon, Mariana S. V. Frazão, Flávio Coelho Ferreira, José Pinhata Otoch

### RESUMEN

Se reporta un caso de acceso del conducto pancreático dorsal por medio de ayuda de ultrasonografía endoscópica en un paciente con cuadro de Páncreas divisum que producía síntomas dolorosos; y que no fué posible su abordaje por PCRE.

**PALABRAS CLAVE:** Páncreas divisum, Ultrasonografía endoscópica, Tratamiento

*Rev. Gastroenterol. Perú; 2012; 32-3: 309-311*

### ABSTRACT

Case report of pancreas divisum dorsal pancreatic duct access with endoscopic ultrasonography help to relief pain in a patient with not possible access by PCRE.

**KEY WORDS:** Pancreas Divisum, Endoscopic Ultrasonography, therapy

### INTRODUCTION

**P**ancreas divisum is the most common congenital pancreatic anatomical variant, usually asymptomatic, occurring in approximately 7% of the autopsies (range 1% - 14%).<sup>1</sup>

It is usually asymptomatic, therefore the treatment (endoscopic or surgical) is indicated in symptomatic patients after thorough investigation and ruling out other causes of pancreatic type abdominal pain and acute pancreatitis.<sup>2,3</sup>

Our objective is to demonstrate a novel technique of EUS-guided access to dorsal pancreatic duct in a patient with pancreas divisum with previous history of acute pancreatitis.

### CASE REPORT

We present here a 32 year-old male with many episodes of acute pancreatitis in the last eight years and no history of biliary stones, previous surgery or biliary manipulation. Magnetic resonance cholangiopancreatography demonstrated showed a normal biliary tree and a dilated non-communication of the dorsal and central ducts with independent drainage sites. As the access through endoscopic retrograde cholangiopancreatography (ERCP) was not possible due to technical difficulty it was used the alternative access through endoscopic ultrasound (EUS).

The EUS image showed hyperechoic spots in the pancreatic parenchyma and dilated dorsal pancreatic duct. EUS guided puncture with a 19G needle, while using doppler to avoid vascular damaged, was realized. It is im-

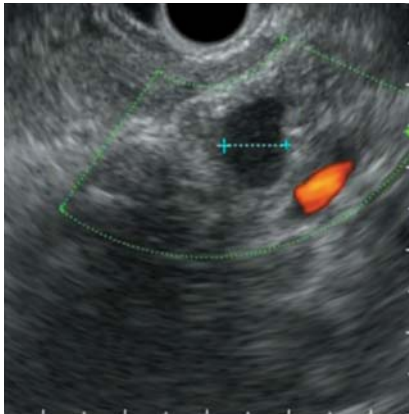


Figure 1: Doppler image showing the location of pancreatic duct and your relation with splenic vessel.

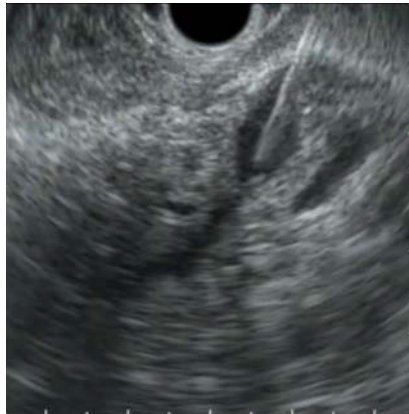

Figure 2: Linear EUS image detailing the puncture into the dorsal pancreatic duct.

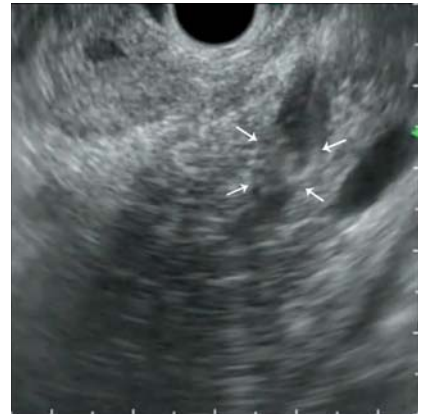


Figure 3: EUS image demonstrates a pancreatography confirming adequate pancreas site. Arrows show the contrast being injected.

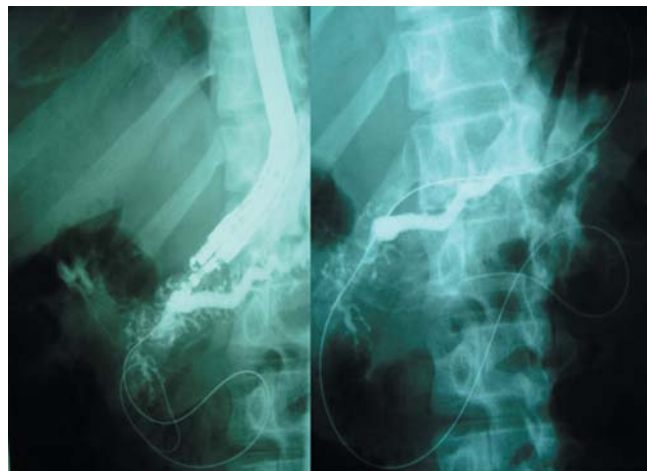


Figure 4: Radiologic image demonstrating the guide-wire located into the duodenum. The left image shows the EUS device.

portant that the dorsal pancreatic duct is in an oblique position on the opposite side of the probe. Contrast was injected to confirm adequate puncture site and appears as shifting hyperechoic images by the EUS view. Then a 0,035-inch guidewire was passed through the minor papilla and positioned deeply into the duodenal lumen. A 8,5 Fr plastic stent was located into pancreatic duct to achieve pancreatic drainage, antegradely.

No immediate or late complications were observed in 8 months of follow up. The laboratory exams demonstrated to be normal after the procedure.

## DISCUSSION

Pancreas divisum is a congenital anomaly developed by a failure of fusion of the ventral and dorsal buds during the embryonic period. Therefore, the drainage of these glands are made separately in the duodenum.<sup>2</sup>

Patients with mild symptoms can be managed conservatively. However, those with recurrent acute pancreati-

tis, chronic pancreatitis or pancreatic-type abdominal pain may require treatment that focuses on decompression and drainage of the dorsal duct, performed endoscopically or surgically.<sup>3</sup>

Both therapies are effective in reducing episodes of acute pancreatitis and pain relief in approximately 80% of patients. Lower rates of response occur in cases of chronic pancreatitis and pancreatic pain (70% and 55% respectively).<sup>3</sup>

RCP is the standard procedure for the decompression of the pancreatic duct but may fail in about 10% of the cases due to previous surgery that changes the gastrointestinal tract, malignant gastroduodenal obstruction, intra or peridiverticular papilla, pancreas *divisum*, among others.<sup>4</sup> However, the identification and puncture of the pancreatic duct can be achieved by endoscopic ultrasound and may allow access and passage of guidewire and therapy of pancreatic duct and duodenal papilla.<sup>5-7</sup>

Wiersema *et al* initially described EUS-guided access to the pancreatic duct. Access to the pancreas was perfor-

med in a patient submitted to gastrectomy with Billroth II reconstruction. Transgastric puncture was achieved resulting in a pancreatography that diagnosed pancreas *divisum*.<sup>8</sup>

The present case demonstrates the feasibility of a new technique in which we can reach the dilated dorsal pan-

creatic duct by EUS guidance in a case with previous failed minor papilla retrograde cannulation. The option should be presented and discussed with the family and surgeons before beginning the procedure.

## REFERENCES

1. SMANIO T. Proposed nomenclature and classification of the human pancreatic ducts and duodenal papillae: study based on 200 post mortems. *Int Surg*. 1969; 52:125-134.
2. QUEST L, LOMBARD M. Pancreas divisum: opinio *divisa*. *Gut* 2000; 47: 317-319.
3. ALEMPIJEVIC T, STIMEC B, KOVACEVIC N. Anatomical features of the minor duodenal papilla in pancreas *divisum*. *Surg Radiol Anat* 2006; 28: 620-624.
4. LEHMAN GA, SHERMAN S. Diagnosis and therapy of pancreas *divisum*. *Gastrointest Endosc Clin N Am*. 1998;8:55-77.
5. SUGA T, NAGAKAWA T, MIYAKAWA H, et al. Clinical features of patients with pancreas *divisum*. *Dig Endosc*. 1994;6:80-86.
6. SAOWAROS V. Pancreas *divisum*: incidence and clinical evaluation in Thai patients. *J Med Assoc Thai*. 1992;75:692-696.
7. MOREIRA VF, MERONO E, LEDO L, et al. Incomplete pancreas *divisum*. *Gastrointest Endosc*. 1991;37:104-107.
8. JACOB L, GEENEN JE, CATALANO MF et al. Clinical presentation and shortterm outcome of endoscopic therapy of patients with symptomatic incomplete pancreas *divisum*. *Gastrointest Endosc* 1999; 49: 53-57.