

Ex vivo and simulator models teaching therapeutic ERCP and EUS: description of SOBED's first course

Modelos ex vivo en simulador en enseñanza de CPRE y ecoendoscopia terapéutica: descripción del primer curso de SOBED

Everson L.A. Artifon^{1a}, Mauro E. Ramirez^{1a}, José C. Ardengh^{1a}, Maria Cristina Sartor^{1a}, Gabriel M. Favaro^{1a}, Emilio Belmonte^{1a}, Julio Lobo^{1a}, Djalma Coelho^{1a}, Julio Pereira-Lima^{1a}, Cesar V. Lopez^{1a}, Sergio E. Matuguma^{1a}, Carlos K. Furuya Jr^{1a}, Julio Pisani^{1a}, Spencer Cheng^{1a}, Marco A. Buch^{1a}, Tomazo Franzini^{1a}, Tiago F. Vilela^{1a}, Ricardo Pessoa^{1a}, Eduardo Bonin^{1a}, Marcos Lera^{1a}, Thaisa S. Nakadomari^{1a}, Leandro Y. Kashiwagui^{1a}, Marlus T. Gerber^{1a}, Ramiro Mascarenhas^{1a}

¹ Sociedad Brasileira de Endoscopia Gastrointestinal (SOBED). São Paulo, Brasil.

^a Miembros Plenos

Recibido: 30-1-2016

Aprobado: 3-3-2016

ABSTRACT

Teaching models in endoscopy are important tools to minimize risks derived from endoscopic procedures, taking into account that therapeutic endoscopy, also known as surgical endoscopy, has greatly developed during the last decade. This results from the fact that minimally invasive procedures present relevant contributions and promote more comfort to patients. In this context, ex vivo teaching models and virtual simulators are important tools to the safe acquisition of abilities. In this article, the Brazilian Society of Digestive Endoscopy presents and describes its first course of therapeutic ERCP and EUS in models of laboratory teaching.

Keywords: *Endoscopy; Cholangiography; Endosonography; Therapeutic uses (source: MeSH NLM).*

RESUMEN

Los modelos de enseñanza en endoscopia son herramientas importantes para minimizar los riesgos de los procedimientos endoscópicos. En la última década la endoscopia terapéutica o también llamada endoscopia-quirúrgica, tuvo gran desarrollo debido a que los procedimientos mínimamente invasivos tienen mejores resultados para la calidad de vida del paciente. En este contexto, los modelos experimentales y animales son herramientas muy importantes para los alumnos. En este artículo de revisión y presentación, los miembros de la Sociedad Brasileira de Endoscopia Digestiva presentan el primer Curso Taller en Ecoendoscopia terapéutica y CPRE en el Congreso Nacional del 2015.

Palabras clave: *Endoscopia; Colangiografía; Ecografía endoscópica; Aplicaciones Terapéuticas (fuente: DeCS BIREME).*

INTRODUCTION

The primary aim of training programs, as defined by international gastrointestinal endoscopy societies, is the safety with which their practitioners are able to perform endoscopic examinations and procedures in a safe, fast and adequate manner. The objective evaluation of abilities for the acquisition of training in endoscopic procedures is determined through a minimum amount of examinations through which proficiency is, in theory, achieved⁽¹⁾.

The acquisition of competence in performing a procedure depends on the learning curve of every individual fellow, so that standardized methods for performance evaluation are necessary, regardless of the number of procedures performed in clinical setting under the supervision of a specialist⁽²⁾.

By contextualizing the specialization in gastrointestinal (GI) endoscopy, in fact, the innovation of learning with

the development of mechanical skills using animal models and simulators for therapeutic procedures in endoscopic retrograde cholangiopancreatography (ERCP) and endoscopic ultrasound (EUS) offers a glimpse into an assisting tool to support the formation of endoscopy professionals.

LITERATURE REVIEW

Disciplines that require the acquisition of technical abilities commend training in clinical setting under the assistance of medical specialists. The long-standing model in specialities requiring procedures presents the advantage of continuous, particularized and theoretically evolutive teaching. The preliminary training in virtual simulators provides the advantage of excluding patients in the initial phases of the learning curve. This may spare patients the discomfort and poor experience of novices in their initial phases throughout conventional clinical training⁽³⁾.

The qualification of gastrointestinal endoscopists is traditionally performed in patients under the supervision of specialists in the field and in clinical setting (conventional bedside training). However, this presents disadvantages, such as procedure time⁽⁴⁾, availability of patients, possible risks to patients, and financial implications⁽⁵⁾. Endoscopic simulators were developed in order to minimize these possible limitations. The American Society for Gastrointestinal Endoscopy Technology Committee recently conducted a literature review aiming at verifying novel impact technological modalities for performing GI endoscopy⁽⁶⁾.

Simulators are models designed to mimetize real life situations for learning and training purposes, as well as improvement of skills. The first endoscopic simulators were described in 1969⁽⁷⁾ and during the 1970s^(8,9). Technological development in recent years permitted the evolution of these devices and, currently, there are complex, computerized simulators.

There are four categories of gastrointestinal endoscopic simulators: mechanical simulators, animal models, combined simulators, and computerized simulators.

Mechanical simulator:

The first mechanical simulator for endoscopic training was constructed of plastic and described in 1974⁽⁹⁾. Mechanical models have the disadvantage of not ideally reproducing reality, as they do not mimetize human tissues. This type of simulator has been replaced by animal models of by virtual computerized simulators⁽⁶⁾.

In vivo simulator – animal model:

Animal models comprise a category of simulators that provides better realistic experience of actual endoscopy. The tactile feel is practically identical to human tissue, although differences in organ thickness and orientation might occur⁽⁶⁾.

Nonetheless, among its disadvantages are the need for specific infrastructure, elevated financial expense, besides the ethical limitation derived from the number of animals necessary⁽⁶⁾. The porcine model has been used as an option for simulating GI endoscopy⁽¹⁰⁾.

Combination of mechanical simulator and explanted animal organs:

These are simulators that combine mechanical simulator and explanted animal organs and are constructed through the composition of plastic parts and explanted animal organs. Prior to their use, specially prepared GI tract organs are placed inside the abdominal cavity of the device⁽⁶⁾. They maintain the realistic characteristic (animal tissue functions as human tissue),

without the need to clear hurdles with ethical and legal problems derived from the use of live animals^(11,12).

The first report of a hybrid method was described in 1995 by Freys et al. that performed an endoscopy in a porcine specimen fixed to cork⁽¹³⁾. The method has been improved and, in 1997, the Erlangen Active Simulator for Interventional Endoscopy (EASIE), was described by Hochberger and Neumann⁽¹⁴⁾ that is even able to simulate blood circulation allowing the training of procedures, such as hemostasis, endoscopic resection, advanced ERCP techniques, lithotripsy, and enteroscopy⁽¹⁵⁾.

Based on EASIE, there are other less complex, costless models, such as those by proposed Velázquez-Aviña and by Matthes-Cohen, re-created neo-papillae with chicken hearts that were further fixed to porcine specimens to simulate duodenal papillae. These models allow the performance of procedures such as, sphincterotomy, papilla cannulation, stent placement, precut, dilation, and stone retrieval^(14,16).

Another proposed, simpler model is the use of 0.4% hyaluronic acid diluted with saline solution in the porcine tissue submucosa to simulate duodenal papillae. In a study comparing this technique in *in vivo* animals and in the combined simulator, the limitation of *ex vivo* specimens that do not reliably simulate bleeding, perforations and respiratory movements was emphasized⁽¹⁷⁾.

In the study conducted by Sedlack *et al.*, training in three ERCP models (combined simulators, *in vivo* animal models and virtual simulators) were compared. As a result, combined simulators were found to score higher grades regarding realism, usefulness, and performance⁽¹⁸⁾. In addition, they were shown to be an inexpensive alternative because virtual simulator are costly and the use of live animals incur costs for their maintenance (feeding, veterinary care, anesthesia during the procedure)⁽¹⁹⁾. Other disadvantage of virtual simulators is the fact that due to their lack of realism, the method is less productive after 20 to 50 procedures, so that it is more useful as training in basic navigation⁽¹⁹⁾.

There are also models described for endoscopic ultrasound (EUS) training with combined simulators. Baron and DeSimio described a model that enables punctions, cyst aspirations, and placement of transmural prostheses. By using sigmoid segments, small intestine and latex tubes, collections, gallbladder, cysts, and the Doppler effect were reproduced⁽²⁰⁾.

The association with other materials is additionally reported, such as the "Mumbai EUS" that uses a polycarbonate bile duct prototype designed by stereolithography in animal liver as interface. This model

aims at the training in EUS of the bile duct drainage (bile duct puncture, guidewire passage, dilation, and stent placement) with realistic EUS and radiologic images ⁽²¹⁾.

In general, the advantages of combined simulators are more realistic situations compared with mechanical models and the possibility to perform therapeutic procedures preventing risks to patients. Their disadvantages include costly preparation, the need for organ availability, and poor simulation of implanted organs ⁽⁶⁾. Unfortunately, there are also limitation, for instance, the impossibility to evaluate complications as bleeding ⁽¹⁶⁾.

Although training in combined simulators, as per rationale, is useful for professional growth; there are not enough data to provide a formal recommendation for the use of simulators in ERCP and EUS in order to speed the learning curve. Therefore, the next step is to evaluate the evolution and acquisition of abilities of professionals by using such simulators, so that scientific data is presented to corroborate their use ⁽²²⁾.

Computerized simulator:

Computerized simulators were developed in the 1980 ^(23,24). Afterwards, with the evolution of software technology, they became more realistic. The interaction of virtual technology with endoscopic images stored in devices permits real-time transmission of movements performed with the endoscope with its accessories. Training graphs are available to evaluate performance and the evolution of required and acquired abilities ⁽⁶⁾.

The virtual simulator GI- Bronch Mentor (*Simbionix*) is comprised of a plastic mannequin, which through its internal sensors, allows the tactile feel at the examination and/or therapeutic moment. This simulator also has an endoscope (Pentax ECS-3840F) to simulate upper and lower GI endoscopy and a duodenoscope (Pentax ED-3440T) to simulate endoscopic retrograde cholangiography ^(25,26).

The tip of the device has sensor that enables the computer to generate a dynamic endoscopic view according to the maneuvers performed by users. This model provides replicated use and no previous preparation is necessary.

A variety of scenarios are available at the moment for diagnostic and endoscopic therapy with different levels of difficulty and complexity. The identification of ability as well as its development and evolution are attained through graphs calculated by the software and provided after the examination finishes ⁽²⁷⁾.

The virtual reality simulator includes programs with 3D-transmitted videos that demonstrate anatomic aspects, pathologic findings, indications,

contraindications, and complications associated with each procedure. Besides, videos that show how to maneuver the endoscope (device insertion, retroversion, biopsy, polypectomy, among others) are included ^(26,27).

This model also provides virtual orientations during the examination, such as technique demonstration and their difficulties. The virtual lumen collapses and expands with insufflation of the device and the patient can reply, verbally, any discomfort or even the need to terminate the procedure. Complications as perforation, bleeding, and vasovagal reaction are demonstrated by the simulator as well ⁽²⁷⁾.

Upon completion of training, performance parameters are provided, including procedure completion time, identification of diagnostic findings, insufflation levels, percentage of mucosa visualized, discomfort experienced by patients, use of virtual attending gastroenterologist, and ability to perform therapeutic maneuvers and procedures ⁽²⁶⁻²⁸⁾.

The advantage of this method is the expression of virtual reality, the device used is safe and similar to the one in clinical practice allowing unlimited training with better cost-benefit ratio in relation to other models.

Ferliitsch and colleagues, in a randomized study, compared the capacity to acquire abilities among beginner and expert endoscopists. As a result, a reduction in examination time in both groups ($p < 0.005$ and $p = 0.002$, respectively) was observed. The difference between the groups of beginners and experts regarding pathologic diagnostics, gastrostomies, retroflexion maneuver, colonoscopies, and adverse events were noted with statistical significance. However, this difference is expected considering that the discrepancy in experience in the group of experts in the field. A significant reduction in the number of complications both in upper and lower GI endoscopy was found when groups were analyzed separately. In addition, device insertion time was observed to be reduced ⁽²⁹⁾.

Teodor and colleagues aimed at the evaluation of virtual simulator role as method of acquisition of technical abilities in GI endoscopy. Twenty-eight participants were divided into three groups according to their experience in endoscopy: medical students, residents, and specialists. All groups were instructed about device use and resources and the type of examination used in colonoscopy. Significant differences were observed in all criteria analyzed in all three groups: time for examination completion ($p < 0.001$), time for "clear mucosal visualization" ($p = 0.001$), percentage of mucosa visualized ($p < 0.001$), efficiency ($p = 0.001$), patient discomfort ($p = 0.004$), loop formation ($p < 0.001$), excessive pressure ($p = 0.001$) ⁽³⁰⁾.

In a prospective, controlled study, 22 residents with no experience in GI endoscopy were randomized in two groups: prior upper GI-endoscopy training in simulator and direct clinical training. The simulator group was found to have a higher rate of completed procedures (87.8% vs. 70%, $p < 0.0001$) and little need for assisting support (41.3% vs. 97.9%). No difference between prior clinical training and no training whatsoever were observed regarding unsuccessful rates of esophageal intubation (4% vs. 2%), number of attempts (means of 1.7 vs. 1.8), and procedure total time (means of 10.7 minutes vs. 12.4 minutes) ⁽¹⁾.

In a prospective, randomized study conducted in 2008, Shirai and colleagues randomly divided 20 residents into two groups: simulator and no simulator. The first group performed endoscopic training for 5 hours in simulator, followed by performance of examination according to the conventional system. The second group performed conventional training from the beginning. Residents were evaluated by two blind specialists for both groups based on the following criteria: device insertion in the esophagus, passage through the esophagogastric junction (EGJ), passage through the pylorus, gastric antrum and bulb examination, retroflexion maneuver, gastric body and duodenal angle visualization. The simulator group was granted a higher score in acquired abilities for insertion in the esophagus, passage through EGJ and pylorus, and gastric antrum and bulb evaluation. In the remainder criteria no statistical differences were observed suggesting that the simulator is useful in technical ability improvement ⁽³¹⁾.

A pilot study with eight endoscopy resident beginners were divided into two groups, with and without prior simulator training, demonstrating improvement in the performance of the participants that used the simulator in the 30 initial colonoscopies

⁽³²⁾. Two other studies compared conventional with simulator training in flexible sigmoidoscopy and verified inferior or similar performance by both groups. Nonetheless, the period of time used by the simulator group was less than three hours ^(33,34).

In a study published in 2003, aiming at evaluating the learning curve through data provided by the (colonoscopy) simulator among three different groups: medicine students, residents and specialists. The authors verified that clinical experience and technical ability of different groups are translated into performance whenever the simulator was used. The specialist group was found to have, with statistical significance, a reduction in time for examination completion ($p < 0.005$) and increase in the percentage of visualized mucosa ($p < 0.001$) in relation to the student and resident groups. Significant improvement

in task performance, percentage of visualized mucosa, and in perforation rate were observed in the three groups throughout the study ⁽³⁾.

Cohen and colleagues ⁽³⁵⁾, in a randomized multicentric study, evaluated 45 first-year endoscopy residents from 16 hospitals in the United States with experience in upper GI endoscopy but with no experience in colonoscopy. The participants were allocated into two groups, one for prior training in simulator and the other without training. After the training period, they underwent the performance of 200 colonoscopies under objective evaluation (successful reach of the splenic angle and cecum, identification of abnormalities and identification of pathologies) as well as subjective (discomfort experienced by patients and global competence). Upon study conclusion, a significant increase in performance of the first group was observed compared to the group without training, after the 20th examination. No statistical difference for subjective criteria was verified, such as discomfort to patients. Despite the initial increase in the simulator group, the score of 90% competence was reached on average with 160 examinations for both groups. This study corroborates the findings by Gerson and colleagues ⁽³⁶⁾ that postulated the benefit in the initial phases with simulator training.

In a randomized study, three groups (novices, trainees with intermediary experience, and experienced endoscopists) were analyzed and improvement in performance was observed in all groups regarding percentage of mucosa evaluated, efficiency (percentage of mucosa evaluated divided by time to complete procedures) and in the percentage of pathologies detected, all with statistical significance ($p < 0.001$) ⁽³⁷⁾.

Simulators have demonstrated improvement in GI endoscopy training in initial learning phases and they can supplement the conventional training model. In a systematic review published in 2012, simulator training was found to reduce risk to patients, decrease procedure time, increase diagnostic accuracy, improve maneuver and procedure performance. However, the majority of studies analyzed presented biases ⁽³⁸⁾.

Gerson and colleagues concluded in literature review published in 2011 that virtual simulators provide advantages in the initial training of GI endoscopy residents. Other studies have demonstrated the increase in both technical and diagnostic abilities with improvement in clinical procedure performance after the use of simulators, with little discomfort for patients. These authors suggested that new studies are necessary to compare the conventional teaching method with virtual simulation method in order to validate the training method ⁽³⁹⁾.

Sedlack and colleagues⁽³²⁾, in a phase I study, assessed various aspects of the simulator in relation to the habitual endoscopic examination. In addition, performance of 21 participants that were divided into three groups according to their experience (seven novices, seven intermediaries and seven expert endoscopists) was analyzed. All subjects were evaluated based on the following criteria: procedure time, time to reach the second portion of the duodenum, percentage of mucosa visualized, efficiency, percentage of clear vision time, percentage of patient discomfort, and pathologies identified. The analysis provided by the participants according to the similarity of simulator to the reality indicated a significant decrease compared to the reality in terms of anatomy and endoscopic maneuvers. Thus, the novice group alone was identified with difference over the other two groups.

In another phase II study published in 2007, the same author compared two groups with four subjects, one with prior training with simulator and the other with direct conventional training. Improvement in the second group was observed regarding patient discomfort and sedation during the five initial days and competency at day 10. Nonetheless, no differences were reported at days 11 and 15⁽⁴⁰⁾.

Studies published to date aim at, mostly, evaluating the acquisition of abilities with the use of simulator alone and it is not possible to infer the efficiency of this method. For this reason, more studies are necessary to demonstrate the role of these programs and their insertion in conventional training.

In the future, this program will be able to assess the competence and formation of residents and graduate students in the area and also improve technical skills of medical specialists⁽⁶⁾.

OBJECTIVE

The objective of this study is to describe and analyze the inclusion of the first hands-on course in therapeutic ERCP and EUS using ex vivo models and (virtual) computerized simulator in the training of technical and diagnostic abilities of GI endoscopists, as well as its application in clinical practice and inclusion in conventional training programs.

MATERIALS AND METHODS

Nine stations were divided into six ex vivo for ERCP, two ex vivo models for EUS, and one virtual simulation station for both ERCP and EUS.

A total of 50 endoscopists with basic proficiency in the procedures and enrolled in the XIV Brazilian Digestive System Week (SBAD in Portuguese), held

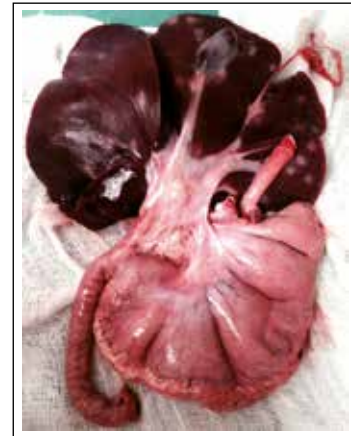

Figure 1. Dissection specimen displaying the model of specimen in use: esophagus, stomach, duodenum, pancreas, liver, and gallbladder.

in Curitiba, PR, Brazil, participated in the course in November 2015. Activities totalled 12 hours allocated in one day. Participants, students and faculty, were properly dressed with surgical gowns, latex gloves, masks and caps. Ex vivo models were prepared by six faculty members 24 hours before procedures and kept in cold storage until didactic activities started (Figure 1). Sanitary surveillance authorization was obtained via temporary protocol notification. All faculty members had proficiency in ERCP and/or EUS. Enrolled students were required to have at least basic training in ERCP or EUS in their affiliated institutions and therefore had notions in both methods. The circuit was comprised by five students per station for 70 minutes and a clockwise rotation was established. At the end of the program, students filled a didactic control form.

Description of Stations:

Station 1 (ERCP: Biliary cannulation and papillotomy)

Model: The standard (ex-vivo) model was made of en-bloc specimen from porcine digestive tract, which was dissected and prepared by associating surgical and anatomic techniques, and that included esophagus, stomach, duodenum, pancreas, liver, and gallbladder. **Specimen preparation:** The specimen was thoroughly cleaned inside the digestive tract to remove food residues and later placed inside a plastic mannequin with the proximal esophagus attached to its mouth orifice. In the second portion of the duodenum, at the mesenteric border, a window with approximately 1 cm in diameter was created and, at this site, duodenal papilla models were inserted and attached. **Duodenal papilla preparation:** The model of duodenal papilla used chicken hearts. In the cardiac apex an orifice was created to mimetize the papillary orifice. From this site, the trajectory considered as the bile duct was made by using a long needle. **Equipment and accessories:** An Olympus CV 180 Evis Exera II trolley was available. A TJF-Q180V duodenoscope and a

bipolar WEN electrocautery were used. Papillotomes and 0.035-mm flexible guidewire manufactured by Boston Scientific, Wilson Cook and Medi-Globe were also used. **Procedures:** Groups with five to six doctors comprised the station and rotated. A 10-minute limit for procedure time was determined for every student. For all groups in the station, the 20 final minutes were assigned to reinforce concepts and maneuvers, repetitions for some students, or demonstrations by the monitor. Upon arrival at the station, the monitor provided a brief explanation about equipment and accessories to be used, orientation about the specimen and how the activity would be performed. The equipment was positioned in the duodenal bulb so that students could position in the second portion of the duodenum, below the papilla. The first student was assisted by a monitor. All students received practical orientations about the equipment (duodenoscope), catheterization techniques, use of its accessories, and how to safely perform papillotomies. After papillotomy completion, equipment was repositioned in the duodenal bulb and every student that completed the procedure replaced the assistant. There was enough time to replace papilla models by new ones. Chicken heart was attached to the duodenal window with two simple surgical stitches. During procedures various questions were raised by students and extensively discussed by the monitor (Figure 2).

Station 2 (ERCP: papillotomy and fistulopapillotomy)

Model: The standard (*ex-vivo*) model was made of en-bloc specimen from porcine digestive tract, which was dissected and prepared by associating surgical and anatomic techniques, and that included esophagus, stomach, duodenum, pancreas, liver, and gallbladder. **Specimen preparation:** The specimen was thoroughly cleaned inside the digestive tract to remove food residues and later placed inside a plastic mannequin with the proximal esophagus attached to its mouth orifice. In the second portion of the duodenum, at the mesenteric border, a window with approximately 1 cm in diameter was created and, at this site, duodenal

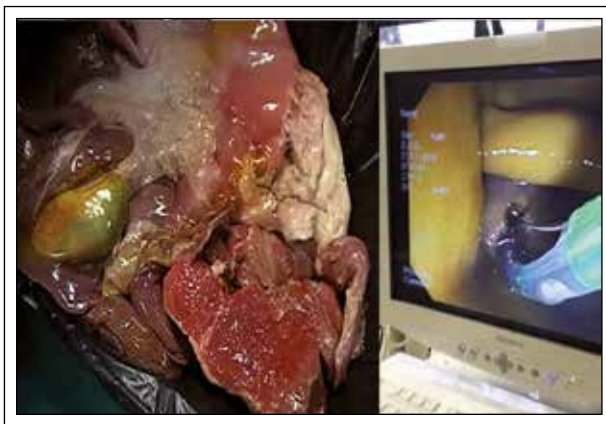

Figure 2. A) Specimen. B) Station.

papilla models were inserted and attached, comprised of chicken heart previously prepared (as explained in station 1). **Equipment and accessories:** An Olympus CV 180 Evis Exera II trolley was available. A TJF-Q180V duodenoscope and a bipolar WEN electrocautery were used. Papillotomes, fistulotomes and 0.035-mm flexible guidewire manufactured by Boston Scientific, Wilson Cook and Medi-Globe were also used. **Procedures:** Groups with five to six doctors comprised the station and rotated. A 10-minute limit for procedure time was determined for every student. For all groups in the station, the 20 final minutes were assigned to reinforce concepts and maneuvers, repetitions for some students, or demonstrations by the monitor. Upon arrival at the station, the monitor provided a brief explanation about equipment and accessories to be used, orientation about the specimen and how the activity would be performed. The equipment was positioned in the second portion of the duodenum, below the papilla, so that every student could receive practical orientations about the equipment (duodenoscope), catheterization techniques, use of its accessories, and how to safely perform papillotomies, start the procedure with bile duct catheterization with papillotome and guidewire. After that, the papillotomy was performed. Finally, the student performed the fistulotomy which resulted in a fistulopapillotomy. After the completion of procedures, equipment was repositioned in the second portion of the duodenum, so that the next student could start the procedure. There was enough time to replace papilla models by new ones. Chicken heart was attached to the duodenal window with two simple surgical stitches (Figure 3).

Station 3 (ERCP: Dilatation of biliary stenosis)

Model: The standard (*ex-vivo*) model was made of en-bloc specimen from porcine digestive tract, which was dissected and prepared by associating surgical and anatomic techniques, and that included esophagus, stomach, duodenum, pancreas, liver, and gallbladder. **Specimen preparation:** The specimen was thoroughly cleaned inside the digestive tract to remove food residues and later placed inside a plastic mannequin with the proximal esophagus attached to its mouth orifice. In the second portion of the duodenum, at the

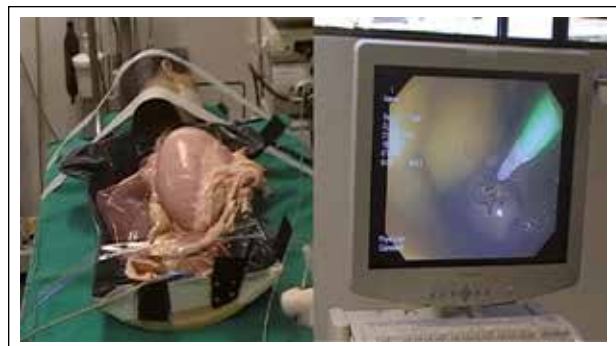


Figure 3. A) Specimen. B) Station.

mesenteric border, a previously created segment of the esophagus was interposed, connecting the liver to the duodenum (common hepatic duct), simulating the extrahepatic biliary duct, that is, the choledochus duct. Anastomosis of the duodeno-esophagostomy, performed with continuous surgical stitches, characterized papilla with previous extensive papillotomy. **Preparation of bile duct and choledocholithiasis stenosis:** In the interposed segment of the esophagus between the liver and duodenum (that simulated the extrahepatic biliary duct) an artificial stenosis was created with 2.0 cotton suture thread fastened externally in a circumference of the organ wall and coffee beans positioned proximally to the stenosis to simulate choledocholithiasis. **Equipment and accessories:** An Olympus CV 180 Evis Exera II trolley was available. A TJF-Q180V duodenoscope was used. Extraction balloon, biliary dilation balloon, and 0.035-mm flexible guidewire manufactured by Boston Scientific, Wilson Cook and Medi-Globe were also used. **Procedures:** Groups with five to six doctors comprised the station and rotated. A 10-minute limit for procedure time was determined for every student. For all groups in the station, the 20 final minutes were assigned to reinforce concepts and maneuvers, repetitions for some students, or demonstrations by the monitor. Upon arrival at the station, the monitor provided a brief explanation about equipment and accessories to be used, orientation about the specimen and how the activity would be performed, and conditions mimetized in the station, in this case, indications of previous extensive papillotomy, stenosis of the medium-distal common hepatic duct with multiple stones located proximally to the stenosis. The duodenoscope was positioned below the duodenal papilla, so that every student could start the procedure with bile duct catheterization with extractor balloon and guidewire, place the guidewire proximally to the stenosis, retrieve the extractor balloon and, at last, introduced the dilator balloon, so that stenosis dilation was performed after adequately positioning this accessory in relation to the stenosis. Rupture of the suture thread encircling the esophageal wall characterized effective dilation. Finally, the extractor balloon was reintroduced to remove coffee beans.

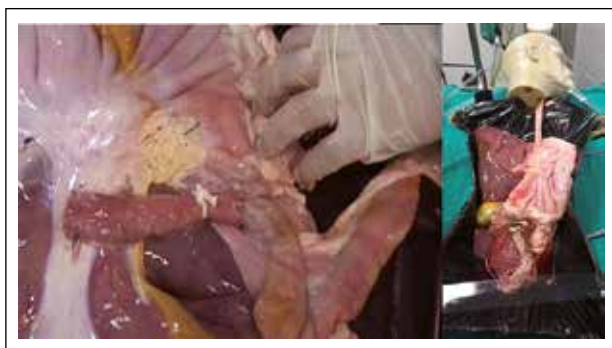

Figure 4. A) Specimen. B) Station.

Every student had the opportunity to perform and assist in procedures, which in some extent enabled reinforcement of maneuvers, concepts, risks, and complications of every station. Student exchange time and re-preparation of artificial conditions (stenosis, bile duct stones) took less than two minutes in a regular and systematic manner. It is important to emphasize that the maneuvers in this experimental model were performed with no fluoroscopy guidance and this fact did not hinder learning by students whatsoever (Figure 4).

Station 4 (ERCP: Plastic biliary stent)

Model: The standard (*ex-vivo*) model was made of en-bloc specimen from porcine digestive tract, which was dissected and prepared by associating surgical and anatomic techniques, and that included esophagus, stomach, duodenum, pancreas, liver, and gallbladder. **Specimen preparation:** The specimen was thoroughly cleaned inside the digestive tract to remove food residues and later placed inside a plastic mannequin with the proximal esophagus attached to its mouth orifice. In the second portion of the duodenum, at the mesenteric border, a window with approximately 1 cm in diameter was created and, at this site, duodenal papilla models were inserted and attached, comprised of chicken heart previously prepared (as explained in station 1). A segment of the esophagus was used interposing the duodenal papilla and the hepatic hilum (as explained in station 2) to simulate the main bile duct. **Equipment and accessories:** An Olympus CV 180 Evis Exera II trolley was available. A TJF-Q180V duodenoscope, papillotomes, 0.035-mm flexible guidewire, and 10.5-Fr plastic stents manufactured by Boston Scientific, Wilson Cook and Medi-Globe were also used. **Procedures:** Groups with five to six doctors comprised the station and rotated. A 10-minute limit for procedure time was determined for every student. For all groups in the station, the 20 final minutes were assigned to reinforce concepts and maneuvers, repetitions for some students, or demonstrations by the monitor. Upon arrival at the station, the monitor provided a brief explanation about equipment and accessories to be used, orientation about the specimen and how the activity would be performed. The duodenoscope was positioned below the duodenal papilla, so that every student could start the procedure with conventional catheterization of the bile duct using papillotome and guidewire and, after that, plastic stent passage. The entire procedure was oriented by 2 professionals experienced in ERCP. One mentor provided orientation directly to candidates and assisted in accessory instrumentation during stent passage. The other acted at the mannequin and assisted in its handling and integrity. The model remained intact up to 30 procedures and, after that, destruction of heart muscle and suture stitch opening were observed, resulting in constant air leakage. This station enabled

the simulation of main stages of bile duct plastic stent passage, including identification of the major duodenal papilla, cannulation, and passage of plastic stent (Figure 5).

Station 5 (ERCP: Metal biliary stent)

Model: The standard (ex-vivo) model was made of en-bloc specimen from porcine digestive tract, which was dissected and prepared by associating surgical and anatomic techniques, and that included esophagus, stomach, duodenum, pancreas, liver, and gallbladder.

Specimen preparation: The specimen was thoroughly cleaned inside the digestive tract to remove food residues and later placed inside a plastic mannequin with the proximal esophagus attached to its mouth orifice. In the second portion of the duodenum, at the mesenteric border, a window with approximately 1 cm in diameter was created and, at this site, duodenal papilla models were inserted and attached, comprised of chicken heart previously prepared (as explained in station 1). A segment of the esophagus was used interposing the duodenal papilla and the hepatic hilum (as explained in station 2) to simulate the main bile duct.

Equipment and accessories: An Olympus CV 180 Evis Exera II trolley was available. A TJF-Q180V duodenoscope, papillotomes, 0.035-mm flexible guidewire, and 60X10-Fr self-expandable metal stents (uncovered, partially and fully covered) manufactured by Boston Scientific were used. **Procedures:** Groups with five to six doctors comprised the station and rotated. A 10-minute limit for procedure time was determined for every student. The 20 final minutes were assigned to every group in the station to reinforce concepts and maneuvers, repetitions for some students, or demonstrations by the monitor. Upon arrival at the station, the monitor provided a brief explanation about equipment and accessories to be used, orientation about the specimen and how the activity would be performed. The duodenoscope was positioned below

the duodenal papilla, so that every student could start the procedure with conventional catheterization of the bile duct using papillotome and guidewire and passage of metal stent subsequently. (Figure 6).

Station 6 (EUS: Pancreatic pseudocyst)

Model: The standard (ex-vivo) model was made of en-bloc specimen from porcine digestive tract, which was dissected and prepared by associating surgical and anatomic techniques, and that included esophagus, stomach, duodenum, pancreas, liver, and gallbladder. In addition, porcine bladder was used separately.

Specimen preparation: The porcine bladder filled internally with saline solution, ultrasound gel, milk, and soluble coffee to simulate a cystic lesion with pus collection. This specimen was sutured on the posterior wall of the gastric body with simple surgical stitches in order to simulate a perigastric cystic lesion.

Equipment and accessories: An Olympus UTC-180 echoendoscope with EU-ME1 processor and 22-G endoscopic ultrasound needle - Expect (Boston Scientific) and Sonotip (Medi-globe) were available.

Procedures: Groups with five to six doctors comprised the station and rotated. A 10-minute limit for procedure time was determined for every student. The 20 final minutes were assigned for every group in the station to reinforce concepts and maneuvers, repetitions for some students, or demonstrations by the monitor. Upon arrival at the station, the monitor provided a brief explanation about equipment and accessories to be used, orientation about the specimen and how the activity would be performed. In this station, the monitor introduced the sector-type echoendoscope and its resources (dimension measurement and power Doppler use) along with concepts about perigastric anechoic image and the echoguided puncture technique, which includes ideal position for punctures, needle type and needle movement. After that, with the sector-type echoendoscope positioned in the gastric

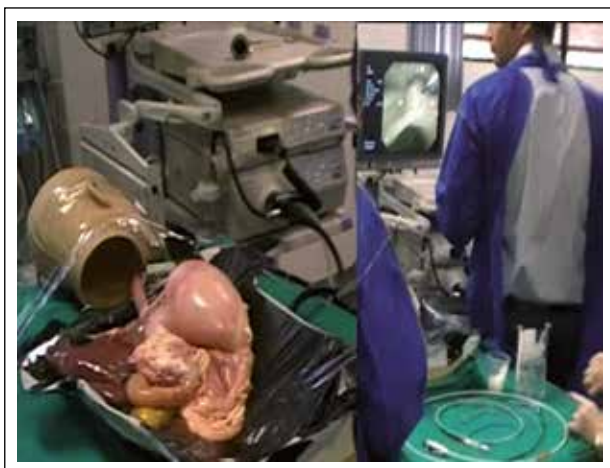

Figure 5. A) Specimen. B) Station.

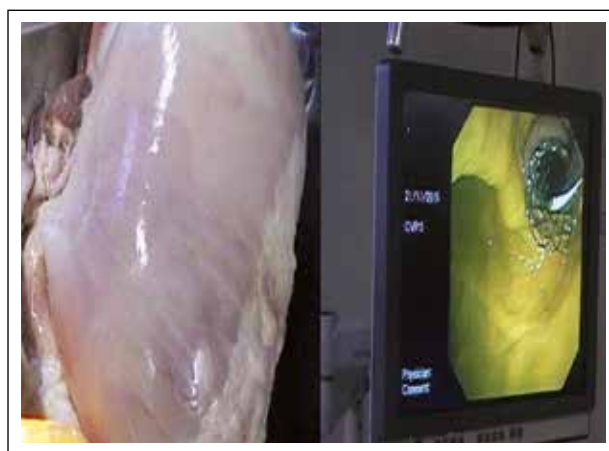

Figure 6. A) Specimen. B) Station.

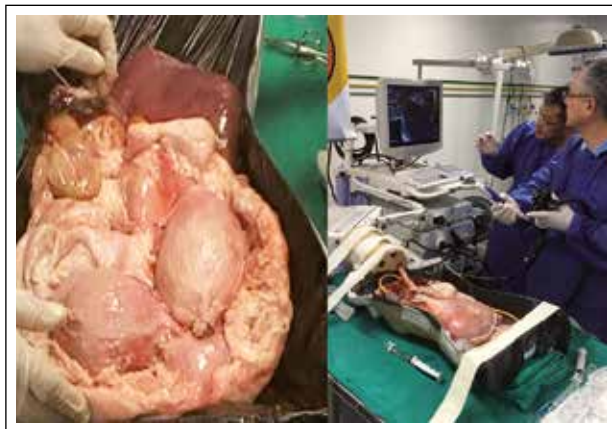

Figure 7. A) Specimen. B) Station.

chamber, every student performed EUS location of cystic lesion and echoguided puncture, respectively (Figure 7).

Station 7 (Simulator: EUS and ERCP)

Simbionix GI Mentor II (Simbionix, Lod, Israel), a computerized simulator to train GI endoscopy, colonoscopy, ERCP, and echoendoscopy, was used. By using the linear-type of echoendoscopy, emphasis on basic notions for echoendoscope handling and identification of main anatomic landmarks, mainly blood vessels in the stomach and duodenum, such as celiac trunk, aorta, diaphragm, pancreas body and tail, and splenic vessels was given. Linear-type echoendoscopy was selected for being the basis for all echoguided procedures, although the equipment can also provide radial-type echoendoscopy training. The simulator enabled the practice of hands-on EUS training through a virtual platform with great realism regarding transducer positioning and structures in the proximity to it. In addition, the display could be divided to present echoendoscopic image and 3D anatomic map side by side, demonstrating the area of array from the ultrasound beam in determined positions. With the simulator, students could practice under constant supervision, advance in learning curve of main anatomic landmarks, and reduce risks on examination of their patients. Although simulators can assist in EUS training, and some studies have already demonstrated their value in GI training and colonoscopy, more controlled, randomized studies proving their efficacy, especially for training in echoendoscopy, are necessary. At last, the equipment requires a module to study the mediastinum and losses the opportunity to provide echo-guided puncture because other therapeutic procedures in GI endoscopic, colonoscopy and ERCP can be already performed with great realism (Figure 8).

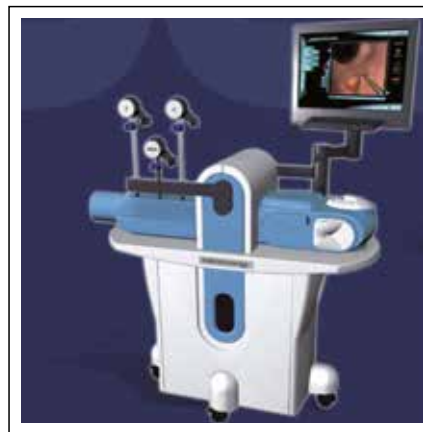

Figure 8. Virtual Simulator, Simbionix.

Station 8 (ERCP: Papilloplasty and biliary cytology brushing)

Model: The standard (*ex-vivo*) model was made of en-bloc specimen from porcine digestive tract, which was dissected and prepared by associating surgical and anatomic techniques, and that included esophagus, stomach, duodenum, pancreas, liver, and gallbladder. **Specimen preparation:** The specimen was thoroughly cleaned inside the digestive tract to remove food residues and later placed inside a plastic mannequin with the proximal esophagus attached to its mouth orifice. In the second portion of the duodenum, at the mesenteric border, a window with approximately 1 cm in diameter was created and, at this site, duodenal papilla models were inserted and attached, comprised of chicken heart previously prepared (as explained in station 1). However, in this case, they were attached with four simple surgical stitches, one at each quadrant. A segment of the esophagus was used, interposing the duodenal papilla and the hepatic hilum (as explained in station 2) to simulate the main bile duct. **Preparation of bile duct stenosis:** In the interposed esophageal segment between the liver and duodenum (that simulated the extrahepatic biliary duct), an artificial stenosis was created with 2.0 cotton suture thread fastened externally in a circumference of the organ wall. **Equipment and accessories:** A Pentax EPK 1000 trolley with duodenoscope was available. Papillotome, 0.035-mm flexible guidewire, CRE dilation balloon and biliary cytology brush from Boston Scientific, Wilson Cook and Medi-Globe were also available. **Procedures:** Groups with five to six doctors comprised the station and rotated. A 10-minute limit for procedure time was determined for every student. For all groups in the station, the 20 final minutes were assigned to reinforce concepts and maneuvers, repetitions for some students, or demonstrations by the monitor. Upon arrival at the station, the monitor provided a brief explanation about

equipment and accessories to be used, orientation about the ex vivo model, how the activity would be performed, and difficulties and conditions simulated in the station. In this case, indications of previous extensive papillotomy, difficult biliary cannulation, and bile duct stenosis. The duodenoscope was positioned below the duodenal papilla, so that every student could start the procedure with cannulation of the bile duct using over-guidewire papillotome and, subsequently, dilation balloon to dilate the biliary stenosis. In a second step, the balloon was retrieved maintaining the guidewire inside the bile duct and a cytology brush was introduced to "collect material" at the site of stenosis. Papilla dilation (papilloplasty) was performed at the end of every cycle. Every three students, the duodenal papilla model was replaced by an intact one. It is important to emphasize that the maneuvers performed in this experimental model were performed with no fluoroscopy guidance and this fact did not hinder learning by students whatsoever (Figure 9).

Station 9 (EUS: Lesion identification, echopuncture, and release of seeds)

Model: The standard (ex-vivo) model was made of en-bloc specimen from porcine digestive tract that was dissected and prepared by associating surgical and anatomic techniques, and included esophagus, stomach, duodenum, pancreas, liver, and gallbladder. **Specimen preparation:** The specimen was thoroughly cleaned inside the digestive tract to remove food residues and later placed inside a plastic mannequin with the proximal esophagus attached to its mouth orifice. **Preparation of nodule lesions:** On the hepatic lobe in contact with the gastric wall, longitudinal incisions were made and grapes with no skin were placed inside them, mimetizing (metastatic or non-metastatic) hepatic nodules. Incisions were sutured with 2.0 cotton thread in order to maintain the presumed lesions at their due sites. **Equipment and accessories:** A 7500 series Pentax echoendoscope with EPK-i processor



Figure 9. A) Specimen. B) Station.

and 22-G endoscopic ultrasound needles - Expect (Boston Scientific) and Sonotip (Medi-Globe) were available. **Procedures:** Groups with five to six doctors comprised the station and rotated. A 10-minute limit for procedure time was determined for every student. For all groups in the station, the 20 final minutes were assigned to reinforce concepts and maneuvers, repetitions for some students, or demonstrations by the monitor. Upon arrival at the station, the monitor provided a brief explanation about equipment and accessories to be used, orientation about the ex vivo model, how the activity would be performed, and difficulties and conditions mimetized in the station. The echoendoscope was positioned below the EGJ, so that every student could start the echoendoscopic array according to the following sequence: locate gallbladder and nodule lesions in hepatic parenchymas, perform echopuncture of nodule lesions, and implant radioactive seeds inside them. At the end of every cycle, the device was removed and repositioned for the next student (Figure 10).

CONCLUSIONS

The association of ex vivo and virtual simulator models for conventional training can optimize the training and abilities of beginners in the specialty of gastrointestinal endoscopy and optimize the cost-benefit ratio as well.

REFERENCES

1. Di Giulio E, Fregonese D, Casetti T, Cestari R, Chilovi F, D'Ambra G, et al. [Training with a computer-based simulator achieves basic manual skills required for upper endoscopy: a randomized controlled trial.](#) *Gastrointest Endosc.* 2004;60(2):196-200.
2. [Principles of training in gastrointestinal endoscopy. From the ASGE.](#) *American Society for Gastrointestinal Endoscopy.* *Gastrointest Endosc.* 1999;49(6):845-53.
3. Mahmood T, Darzi A. [A study to validate the colonoscopy simulator.](#) *Surg Endosc.* 2003;17(10):1583-9.
4. McCashland T, Brand R, Lyden E, de Garmo P. [The time and financial impact of training fellows in endoscopy. CORI Research Project. Clinical Outcomes Research Initiative.](#) *Am J Gastroenterol.* 2000;95(11):3129-32.

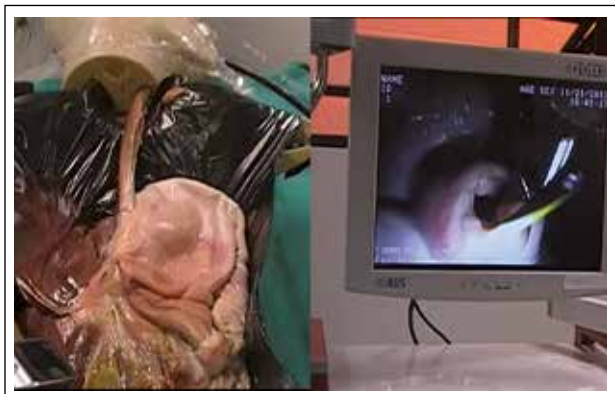

Figure 10. A) Specimen. B) Station.

5. Bini EJ, Firoozi B, Choung RJ, Ali EM, Osman M, Weinsel EH. [Systematic evaluation of complications related to endoscopy in a training setting: a prospective 30-day outcomes study](#). *Gastrointest Endosc.* 2003;57(1):8-16.
6. Desilets DJ, Banerjee S, Barth BA, Kaul V, Kethu SR, Pedrosa MC, et al. [Endoscopic simulators](#). *Gastrointest Endosc.* 2011;73(5):861-7.
7. Markman HD. [A new system for teaching proctosigmoidoscopic morphology](#). *Am J Gastroenterol.* 1969;52(1):65-9.
8. Heinkel VK, Kimming JM. [Megenphantome zur ausbling in der gastrokamera-magenuntersuhung](#) [German]. *Z Gastroenterol.* 1971;9(5):331-40.
9. Classen M, Ruppin H. [Practical endoscopy training using a new gastrointestinal phantom](#). *Endoscopy.* 1974;6(2):127-31.
10. Nelson DB, Bosco JJ, Curtis WD, Faigel DO, Kelsey PB, Leung JW, et al. [Technology status evaluation report: endoscopy simulators: May 1999](#). *Gastrointest Endosc.* 2000;51(6):790-2.
11. Blackburn SC, Griffin SJ. [Role of simulation in training the next generation of endoscopists](#). *World J Gastrointest Endosc.* 2014;6(6):234-9.
12. Parra-Blanco A, González N, Ortiz-Fernández-Sordo J, Ordieres C. [Animal models for endoscopic training: do we really need them?](#) *Endoscopy.* 2013;45(6):478-84.
13. Dunkin BJ. [Flexible endoscopy simulators](#). *Semin Laparosc Surg.* 2003;10(1):29-35.
14. Matthes K, Cohen J. [The Neo-Papilla: a new modification of porcine ex vivo simulators for ERCP training \(with videos\)](#). *Gastrointest Endosc.* 2006;64(4):570-6.
15. Hochberger J, Maiss J. [Currently available simulators: ex vivo models](#). *Gastrointest Endosc Clin N Am.* 2006;16(3):435-49.
16. Velázquez-Aviña J, Sobrino-Cossío S, Chávez-Vargas C, Sulbaran M, Mönkemüller K. [Development of a novel and simple ex vivo biologic ERCP training model](#). *Gastrointest Endosc.* 2014;80(6):1161-7.
17. Itoi T, Gotoda T, Baron TH, Sofuni A, Itokawa F, Tsuji S, et al. [Creation of simulated papillae for endoscopic sphincterotomy and papillectomy training by using in vivo and ex vivo pig model \(with videos\)](#). *Gastrointest Endosc.* 2013;77(5):793-800.
18. Sedlack R, Petersen B, Binmoeller K, Kolars J. [A direct comparison of ERCP teaching models](#). *Gastrointest Endosc.* 2003;57(7):886-90.
19. Sedlack RE. [The state of simulation in endoscopy education: continuing to advance toward our goals](#). *Gastroenterology.* 2013;144(1):9-12.
20. Baron TH, DeSimio TM. [New ex-vivo porcine model for endoscopic ultrasound-guided training in transmural puncture and drainage of pancreatic cysts and fluid collections \(with videos\)](#). *Endosc Ultrasound.* 2015;4(1):34-9.
21. Dhir V, Itoi T, Fockens P, Perez-Miranda M, Khashab MA, Seo DW, et al. [Novel ex vivo model for hands-on teaching of and training in EUS-guided biliary drainage: creation of "Mumbai EUS" stereolithography/3D printing bile duct prototype \(with videos\)](#). *Gastrointest Endosc.* 2015;81(2):440-6.
22. Ekkelenkamp VE, Koch AD, Man RA, Kuipers EJ. [Training and competence assessment in GI endoscopy: a systematic review](#). *Gut.* 2016;65(4):607-15.
23. Williams CB, Baillie J, Gillies DF, Borislow D, Cotton PB. [Teaching gastrointestinal endoscopy by computer simulation: a prototype for colonoscopy and ERCP](#). *Gastrointest Endosc.* 1990;36(1):49-54.
24. Noar MD. [Robotics interactive endoscopy simulation of ERCP/sphincterectomy and EGD](#). *Endoscopy.* 1992;24 Suppl 2:539-41.
25. Park J, MacRae H, Musselman LJ, Rossos P, Hamstra SJ, Wolman S, et al. [Randomized controlled trial of virtual reality simulator training: transfer to live patients](#). *Am J Surg.* 2007;194(2):205-11.
26. Pawa R, Chuttani R. [Benefits and limitations in endoscopic training](#). *Tech Gastrointest Endosc.* 2011;13(3):191-8.
27. Clark JA, Volchok JA, Hazey JW, Sadighi PJ, Fanelli RD. [Initial experience using an endoscopic simulator to train surgical residents in flexible endoscopy in a community medical center residency program](#). *Curr Surg.* 2005;62(1):59-63.
28. Koch AD, Buzink SN, Heemskerk J, Botden SMBI, Veenendaal R, Jakimowicz JJ, et al. [Expert and construct validity of the Symbionix GI Mentor II endoscopy simulator for colonoscopy](#). *Surg Endosc.* 2008;22(1):158-62.
29. Ferlitsch A, Glauninger P, Gupper A, Schillinger M, Haefner M, Gangl A, et al. [Evaluation of a virtual endoscopy simulator for training in gastrointestinal endoscopy](#). *Endoscopy.* 2002;34(9):698-702.
30. Grantcharov TP, Carstensen L, Schulze S. [Objective assessment of gastrointestinal endoscopy skills using a virtual reality simulator](#). *JLS.* 2005;9(2):130-3.
31. Shirai Y, Yoshida T, Shiraishi R, Okamoto T, Nakamura H, Harada T, et al. [Prospective randomized study on the use of a computer-based endoscopic simulator for training in esophagogastroduodenoscopy](#). *J Gastroenterol Hepatol.* 2008;23(7 Pt 1):1046-50.
32. Sedlack RE, Kolars JC. [Computer simulator training enhances the competency of gastroenterology fellows at colonoscopy: results of a pilot study](#). *Am J Gastroenterol.* 2004;99(1):33-7.
33. Gerson LB, Van Dam J. [A prospective randomized trial comparing a virtual reality simulator to bedside teaching for training in sigmoidoscopy](#). *Endoscopy.* 2003;35(7):569-75.
34. Sedlack RE, Kolars JC, Alexander JA. [Computer simulation training enhances patient comfort during endoscopy](#). *Clin Gastroenterol Hepatol.* 2004;2(4):348-52.
35. Cohen J, Cohen SA, Vora KC, Xue X, Burdick JS, Bank S, et al. [Multicenter, randomized, controlled trial of virtual-reality simulator training in acquisition of competency in colonoscopy](#). *Gastrointest Endosc.* 2006;64(3):361-8.
36. Gerson LB, Van Dam J. [Technology review: the use of simulators for training in GI endoscopy](#). *Gastrointest Endosc.* 2004;60(6):992-1001.
37. Moorthy K, Munz Y, Jiwanji M, Bann S, Chang A, Darzi A. [Validity and reliability of a virtual reality upper gastrointestinal simulator and cross validation using structured assessment of individual performance with video playback](#). *Surg Endosc.* 2004;18(2):328-33.
38. Walsh CM, Sherlock ME, Ling SC, Carnahan H. [Virtual reality simulation training for health professions trainees in gastrointestinal endoscopy](#). *Cochrane Database Syst Rev.* 2012;(6):CD008237.
39. Parent R, Gerson LB. [Realistic simulation of diagnostic endoscopy](#). *Tech Gastrointest Endosc.* 2011;13(3):161-6.
40. Sedlack RE. [Validation of computer simulation training for esophagogastroduodenoscopy: pilot study](#). *J Gastroenterol Hepatol.* 2007;22(8):1214-9.

Correspondence:

Everson L.A. Artifon
 Rua Guimaraes Passos, 260/apto 121
 Sao Paulo. ZC: 04107-030; Brazil
 E-mail: eartifon@hotmail.com