

Rectal syphilis in a HIV patient from Peru

Sífilis rectal en un paciente con VIH de Perú

Christian Alcántara Figueroa¹, Nora Nuñez Calixto², Gloria Vargas Cárdenas², Cesar Chian García³

¹ Ex-Médico Residente de Gastroenterología, Hospital Nacional Arzobispo Loayza. Lima, Perú.

² Médico Asistente de Gastroenterología, Hospital Nacional Arzobispo Loayza. Lima, Perú.

³ Médico Asistente de Servicio de Patología, Hospital Nacional Arzobispo Loayza. Lima, Perú.

Recibido: 9-9-17

Aprobado: 17-12-18

ABSTRACT

We present the case of a 53-year-old male patient, a man who had sex with men. He described the presence of inguinal adenopathy and non-painful ulcer with indurated edges on his penis that heal spontaneously after 3 months. In the same period of time the patient presented: tenesmus, bleeding and rectal pain. In the proctoscopy was observed at the level of the rectum: deep ulcer with regular and indurated edges, ulcerated bed with abundant mucus; The rectal mucosa around the ulcer had multiple circumferential erosions 2-4 mm in diameter. The biopsy showed infiltration of lymphomonocollar cells and granulomas. The HIV ELISA test was positive, CD 4: 275 cel./uL, HIV viral load: 10 300 copies / ml, VDRL: Non-reactive, FTA-Abs: 1/10 (positive). Warthin-Starry staining was used in the rectal ulcer biopsy sample identifying spirochetes. After the administration of benzathine Penicillin G, the symptoms and lesions in the rectal region were resolved. Likewise, antiretroviral treatment was initiated. Ulcerative and erosive proctitis is common in people living with HIV infection, however, it is rare to identify spirochetes in the biopsy sample.

Keywords: *Syphilis; Rectum; HIV (source: MeSH NLM).*

RESUMEN

Presentamos el caso de un paciente varón de 53 años de edad, un hombre que tenía sexo con hombres. El describió la presencia de adenopatía inguinal y úlcera no dolorosa con bordes indurados en su pene que cicatrizó espontáneamente luego de 3 meses. En el mismo periodo de tiempo el paciente presentó: tenesmo, sangrado y dolor rectal. En la proctoscopia se observó a nivel del recto: úlcera profunda con bordes regulares e indurados, lecho ulceroso con abundante moco; la mucosa rectal alrededor de la úlcera tenía múltiples erosiones circunferenciales de 2-4 mm de diámetro. La biopsia mostró infiltrado de células linfomonocleares y granulomas. El examen de ELISA VIH resultó positivo, CD 4: 275 cel./uL, carga viral VIH: 10 300 copias / ml, VDRL: No reactivo, FTA-Abs: 1/10 (Positivo). Se utilizó la tinción de Warthin-Starry en la muestra de biopsia de úlcera rectal identificando espiroquetas. Luego de la administración de Penicilina G benzatinica, se resolvieron los síntomas y lesiones en la región rectal. Así mismo se inició el tratamiento antirretroviral. La proctitis ulcerosa y erosiva es frecuente en personas que viven con infección por VIH, sin embargo, es raro identificar espiroquetas en la muestra de biopsia.

Palabras clave: *Sífilis; Recto; VIH (fuente: DeCS BIREME).*

INTRODUCTION

Syphilis is an infection caused by the bacterium *Treponema pallidum*. During the initial phase of infection, the organism spreads widely, setting the stage for later manifestations. If the treatment of syphilis is postponed, very significant complications can occur at the cardiovascular and neurological level.

The presence of infection by the immunodeficiency virus (HIV) modifies the clinical presentation of syphilis with greater involvement of the organs, atypical and florid skin rashes; besides the fastest progression to neurosyphilis. The results of serological tests for syphilis can also be modified in patients infected with HIV. Benzathine penicillin G is used for the treatment of primary and secondary syphilis.

We present the case of a patient with human immunodeficiency virus infection who presented with rectal syphilis, and we describe the diagnostic approach of rectal ulcer in the patient with HIV.

CASE REPORT

Male patient of 53 years of age, he reported being a man who has sex with other men. Patient described having presented ulcers in the penis and inguinal adenopathy that he resolved spontaneously after three weeks, then he presented rectal bleeding, 4 -5 episodes per day, in addition to pain and rectal tenesmus; reason for which decided to go to the hospital (National Hospital Arzobispo Loayza of Lima - Peru). Laboratory tests revealed: Hemoglobin 10 gr / dl, leukocytes: 7 020 mm³; platelets 290,000 mm³, HIV I - II Ag / Ac ELISA: positive, viral load of HIV: 103,000 copies / ml, CD4 + lymphocytes (T - helper): 275 cells / uL, VDRL: non - reactive; TLC - ABS: positive; stool culture: negative. No parasites were identified in the fecal tests.

In proctoscopy (Figure 1), an ulcer extending to approximately 70% of the rectal circumference was observed in the distal rectum, rectal ulcer with well defined and firm edges, the ulcer bed covered with abundant mucus. The mucosa around the ulcer

presented multiple circumferential erosions of 2 to 4 mm. The biopsy showed a severe inflammatory infiltrate composed of lymphomononuclear cells and granulomas. The Warthin-Starry stain was able to identify spirochetes. For the diagnosis of rectal syphilis, the patient received penicillin G benzathine via intramuscular (2 400 000 IU) for the only time; resolving gastrointestinal symptoms and healing of rectal ulcer in posterior proctoscopy study. In the Infectious Disease Service of the same patient hospital, he began his antiretroviral treatment.

DISCUSSION

Syphilis is a sexually transmitted disease, caused by the bacterium *Treponema pallidum*, a microaerophilic bacterium shaped like a corkscrew, this bacterium can not be grown in the laboratory. Syphilis is characterized by periods of overt disease and periods of latent infection. In patients with HIV infection, the clinical presentation of syphilis may have greater involvement of organs, for example: atypical skin rashes, faster progression to neurosyphilis. The results of serological tests for syphilis can also be modified in patients infected with HIV. False positive nontreponemal tests can be seen during pregnancy, systemic lupus erythematosus, chronic liver disease and HIV infection⁽¹⁾.

The diagnosis of syphilis is made by adding the history of sexual exposure, the identification of clinical signs and the interpretation of serological tests. The coinfection of HIV and syphilis is frequent, because both share the same route of transmission. HIV infection can facilitate infection by syphilis and vice versa^(2,3).

In primary syphilis the presence of an ulcer (called a chancre) can be observed, which usually appears two or three weeks after sexual contact with the infected person. The papule that causes the chancre is painless, it can grow between 0.5 and 2 cm in diameter, this lesion is ulcerated, with firm margins, indurated and clean bed. The regional lymph nodes tend to increase in size, are of gummy, non-painful consistency and bilateral location⁽⁴⁾.

Syphilis ulcers are usually unique, however multiple ulcers have been frequently described in HIV-infected persons^(5,6). Rectal syphilis is one of the great masqueraders due to its variable symptoms including itching, bleeding, tenesmus, urgency of defecation, and anal discharge, which may be purulent, mucoid, or blood stained⁽⁷⁾. Therefore, physicians should be aware of its various manifestations to avoid inappropriate treatments.

Cases of primary rectal syphilis are poorly reported⁽⁸⁻¹⁰⁾, but their frequency seems to be higher, since it is the third cause of anorectal infections among young men who have sex with other men, being the first cause of rectal ulcer is caused by herpes simplex and gonococcus^(11,12). The differential diagnosis includes infectious or non-infectious diseases such as *Chlamydia trachomatis*, cytomegalovirus, herpes simplex virus, tuberculosis, amebiasis, solitary rectal ulcer syndrome, neoplasia or Crohn's disease⁽⁷⁾. We can also suspect mycosis such as histoplasmosis or paracoccidioidomycosis if the patient comes from endemic areas. These mycoses can present as colo-rectal ulcers and may show granulomas in the biopsy⁽¹³⁻¹⁵⁾.

In this clinical case, we suspect sexually transmitted infections due to the patient's sexual behavior.

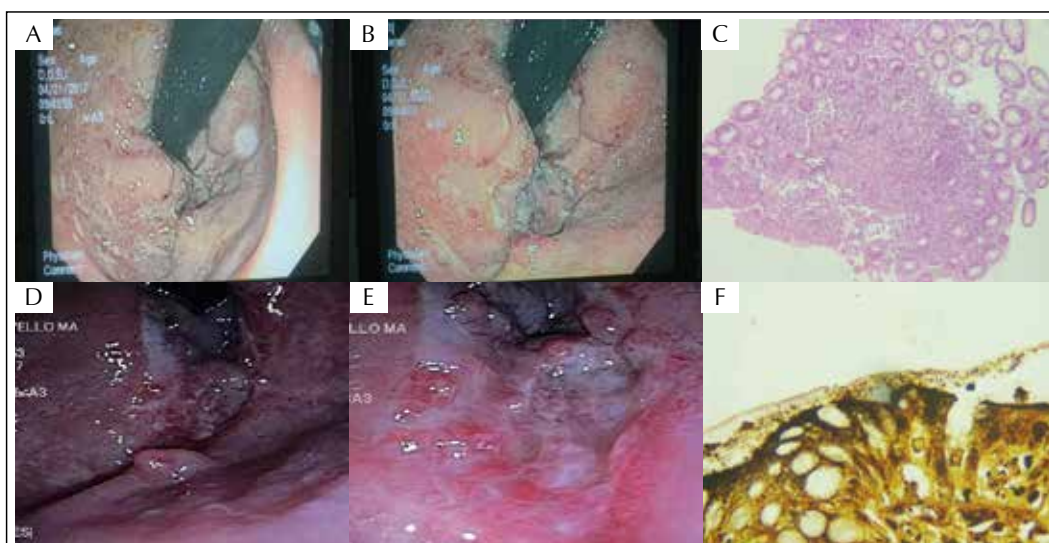


Figure 1. Rectum: A and B: Rectal ulcer with well-defined borders and abundant mucus covers the ulcer bed. Circumferential erosions of 2 to 4 mm in the mucosa around the rectal ulcer. The haematoxylin-eosin stain shows an abundant inflammatory infiltrate composed of lymphomononuclear cells and granulomas. D and E. Cured rectal ulcer after treatment. F. Warthin-Starry coloration: identifies spirochetes.

Proctoscopy was performed by taking biopsies of the lesion; the neoplastic etiology was ruled out, later it was sought to exclude infectious diseases. The nucleic acid amplification tests of *Chlamydia trachomatis*, although not yet authorized for this anatomical site, are more sensitive than the *Chlamydia trachomatis* culture. PCR is also the best method to detect cytomegalovirus. There are few studies on the association of rectal syphilis and viral load in patients coinfecting with HIV⁽¹⁶⁾. The most sensitive methods for the detection of *Treponema pallidum* are immunohistochemical or Warthin-Starry staining.

The limitation of molecular tests is that they are not available in public health hospitals and are also very expensive in Peru. The biopsy of our patient was negative for cancer, but showed some non-caseating granulomas, so the possibility of infection by *Chlamydia trachomatis* or syphilis was considered. Warthin Starry's stain showed *Treponema pallidum*, so we treated the patient with intramuscular penicillin G benzathine (2 400 000 IU IM once). The patient reported relief of rectal bleeding and pain one week after receiving treatment. The HIV-infected patient with syphilis should be treated with the same regimens as those recommended for patients who are seronegative to HIV. Clinical examination and serological tests with a nontreponemal test (eg, RPR) should be performed every 6 to 12 months. The titles should be reviewed more frequently if the patient is infected with HIV, follow-up is uncertain and reinfection is a concern⁽¹⁷⁾. An open randomized clinical trial compared the efficacy of single-dose and three-dose benzathine penicillin regimens for the treatment of early syphilis in 64 people infected with HIV. RPR titers were controlled every three months, and treatment success was defined as a decrease in RPR titers of > 2 dilutions during the 12-month follow-up. Success rates were 93 percent in single doses and 100 percent in groups of three doses, without statistically significant differences between regimens⁽¹⁸⁾. The diagnosis of syphilis is very important because if we do not treat this disease properly, cardiovascular or neurological manifestations may appear, as explained above.

We conclude that the etiology of a rectal ulcer in a male patient who has sex with other men is probably infectious, as in this case rectal ulcer due to syphilis. It is important to have the etiology of a rectal ulcer to offer the appropriate treatment in a timely manner, avoiding serious complications such as tertiary syphilis.

Conflicts of interest: None

BIBLIOGRAPHIC REFERENCES

1. Seña AC, White BL, Sparling PF. Novel *Treponema pallidum* serologic tests: a paradigm shift in syphilis screening for the 21st century. *Clin Infect Dis*. 2010;51(6):700-8.
2. Ganesan A, Fieberg A, Agan BK, Lalani T, Landrum ML, Wortmann G, et al. Results of a 25-year longitudinal analysis of the serologic incidence of syphilis in a cohort of HIV-infected patients with unrestricted access to care. *Sex Transm Dis*. 2012;39(6):440-8.
3. Centers for Disease Control and Prevention (CDC). Primary and secondary syphilis among men who have sex with men—New York City, 2001. *MMWR Morb Mortal Wkly Rep*. 2002;51(38):853-6.
4. Sparling PF. Natural history of syphilis. In: Holmes KK, Mardh PA, Sparling PF, Wiesner PJ, editors. *Sexually Transmitted Diseases*. New York: McGraw-Hill; 1990. p. 213.
5. French P. Syphilis. *BMJ*. 2007;334(7585):143-7.
6. Rompalo AM, Joesoef MR, O'Donell JA, Augenbraun M, Brady W, Radolf JD, et al. Clinical manifestations of early syphilis by HIV status and gender: results of the syphilis and HIV study. *Sex Transm Dis*. 2001;28(3):158-65.
7. Myung C. Rectal Syphilis Mimicking Rectal Cancer. *Yonsei Med J*. 2010;51(2):276-8.
8. Lieberman W. Syphilis of the rectum. *Rev Gastroenterol*. 1951;18:67-9.
9. Bassi O, Cosa G, Colavolpe A, Argentieri R. Primary syphilis of the rectum—endoscopic and clinical features. Report of a case. *Dis Colon Rectum*. 1991;34(11):1024-6.
10. Nakamura T, Kishimoto K, Shimozawa N, Koike S, Shimizu T, Kumeda S, et al. A case of rectal lues. *Nippon Shokakibo Gakkai Zasshi*. 2000;97(2):195-8.
11. Quinn TC, Corey L, Chaffee RG, Schuffler MD, Brancato FP, Holmes KK. The etiology of anorectal infections in homosexual men. *Am J Med*. 1981;71(3):395-406.
12. Drusin LM, Homan WP, Dineen P. The role of surgery in primary syphilis of the anus. *Ann Surg*. 1976;184(1):65-7.
13. Verona R, Gamarra J, Nava E, Chávez M, Perez J, Valdivia M. Paracoccidioidomycosis colónica: reporte de un caso. *Rev Gastroenterol Peru*. 1998;18(3):285-91.
14. Alcántara C, Verástegui R, Aphan M, Cáceres D. Paracoccidioidomycosis colónica en un hospital de Lima - Perú: reporte de 4 casos. *Rev Gastroenterol Peru*. 2017;37(1):77-81.
15. Alcántara C, Sánchez V. Histoplasmosis del colon y recto en un paciente de Perú. *Rev Gastroenterol Peru*. 2016;36(4):365-8.
16. Arnold CA, Limketkai BN, Illei PB, Montgomery E, Voltaggio L. Syphilitic and Lymphogranuloma venereum (LGV) proctocolitis: clues to a frequently missed diagnosis. *Am J Surg Pathol*. 2013;37(1):38-46.
17. Workowski KA, Bolan GA; Centers for Disease Control and Prevention. Sexually transmitted diseases treatment guidelines, 2015. *MMWR Recomm Rep*. 2015;64:1-137.
18. Andrade R, Rodríguez-Barradas MC, Yasukawa K, Villarreal E, Ross M, Serpa JA. Single dose versus 3 doses of Intramuscular Benzathine Penicillin for early syphilis in HIV: A randomized clinical trial. *Clin Infect Dis*. 2017;64(6):759-64.

Correspondence:

Christian Eduardo Alcántara Figueroa

Address: Av. Residencial 140, Urb, Las Palmeras del Golf. Trujillo, Perú.

E-mail: christian378@hotmail.com